

MULTIFOCAL ANAPLASTIC ASTROCYTOMA IN THE LUMBAR-SACRAL SPINAL CORD OF A 7 YEAR-OLD BLOOD HOUND

NE Vecchio, TA Tobias

MedVet Memphis Specialty Hospital, Memphis, TN, USA

Abstract: *Anaplastic astrocytomas are extremely uncommon tumors of the spinal cord in dogs. A 7 year old, female spayed Blood Hound dog was presented for evaluation of mild right rear leg lameness. The lameness was strictly unilateral with no other significant abnormalities in the physical and neuro-orthopedic examinations. The severity of the lameness progressed rapidly to be non-weight bearing with severe conscious proprioceptive deficits and muscle atrophy. The dog was euthanized at the owner's request. Post-mortem examination and histopathological analysis revealed a multifocal anaplastic astrocytoma arising from the lumbar-sacral segments of the spinal cord.*

Key Words: astrocytoma, spinal cord, dog

ASTROCITOMA MULTIFOCAL ANAPLÁSICO EN EL SEGMENTO LUMBOSACRO DE LA MÉDULA ESPINAL EN UNA PERRA BLOOD HOUND DE 7 AÑOS

Resumen: *Los astrocitomas anaplásicos son tumores muy raramente reconocidos en la médula espinal en caninos. Una perra Blood Hound, castrada, de 7 años de edad fue presentada para evaluación de una leve claudicación del miembro pelviano derecho. Ningún otro hallazgo significativo fue notado en el examen físico como así tampoco en el neuro-ortopédico. La severidad de la claudicación progresó rápidamente al punto de que el animal no podía soportar peso sobre la pierna afectada. Severas deficiencias neurológicas y atrofia muscular fueron observadas. La perra fue sacrificada a pedido de los dueños. La evaluación post-mortem y estudios histopatológicos revelaron dos tumores en los segmentos lumbar y sacro de la médula espinal. Los tumores fueron diagnosticados como atrocitomas anaplásicos.*

Palabras clave: astrocitoma, médula espinal, canino

Fecha de recepción: 30/05/07

Fecha de aprobación: 07/03/08

Dirección para correspondencia: Nicolas Vecchio, Nicolás Vecchio, MedVet Memphis Specialty Hospital 830 North Germantown Parkway, Suite #105, Memphis, TN, USA - 38018 Phone: 001-901-624-9002 - Fax: 001-901-624-9014 **E-mail:** nicovecchio@yahoo.com

INTRODUCTION

Anaplastic astrocytomas have been rarely described as primary tumors of the spinal cord in dogs and cats. Spinal canal tumors are divided into three types according to their relationship with respect to the spinal cord and dura (1, 2, 3, 4): extradural, outside of the spinal cord (50%) (4); intradural extramedullary, within the dura but not invading the neural substance of the spinal cord (35%) (4); and intramedullary, growing within the substance of the cord (15%) (4). Most canine spinal cord tumors are found extradurally, whereas primary intradural tumors are less likely (2, 9). Previous studies have shown that only 3% of canine patients with spinal cord tumors were diagnosed with astrocytomas (2, 6) and there is only one reported case of anaplastic astrocytoma (10). Most affected dogs are middle age 8 and large breeds 9 and brachicephalic dogs seem to be overrepresented (3, 8). Both sexes are affected equally. To the authors' knowledge, there is no previous report of a multifocal anaplastic astrocytoma in the spinal cord of a dog.

CASE DESCRIPTION

A 7 year-old spayed female Blood Hound was presented with an acute onset of progressively worsening strictly unilateral lameness of the rear right leg. Orthopedic and neurological examinations were performed. The dog was initially treated nonspecifically with a NSAID (meloxicam 0.1 mg/kg PO once a day) and, seven days later, with an intravenous injection of 30 mg of dexamethasone. Radiographs of lower back, hips, and knee were taken and submitted to a board-certified radiologist. Necropsy was performed and the spinal cord and muscle samples of lumbar epiaxial muscles, biceps femoralis, and quadriceps were sent for histopathological study to Colorado State College of Veterinary Medicine. Standard preparation for histopathological analysis was used.

RESULTS

The animal progressively worsened and seven days after the first consultation, the patient had lost significant motor function to its rear right leg, but was still able to bear weight. Severe neurological deficits and mild muscle atrophy were noticed at this time. An intravenous injection of 30 mg of dexamethasone had no beneficial effect. Two weeks after initial presentation the patient was unable to bear weight on the affected right rear limb. Neuro-orthopedic examination revealed absence of paw positioning, patellar reflex, and withdrawal in the right rear limb. In the left rear limb, hyper-reflexia of the patellar reflex was noted.

Neuroanatomically, the problem localized

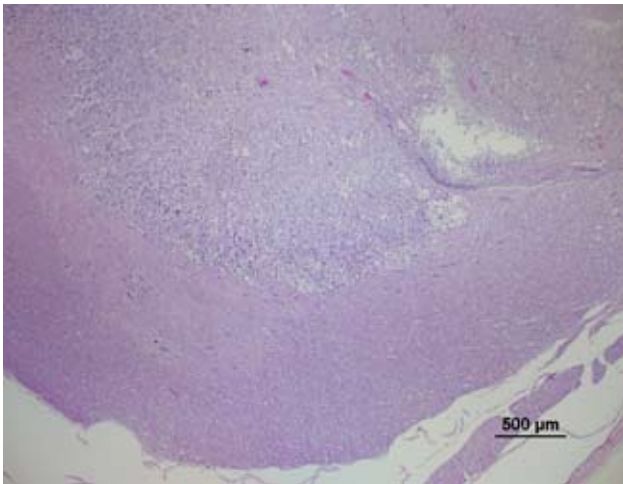
to L4-S1 spinal segments (worse L4-L6), but remained strictly right sided. No significant spinal pain was observed. The radiologist described degenerative changes of the lumbar spine, but no other abnormalities. Computed tomography and/or magnetic resonance imaging studies were declined by the dog's owner. Because of its rapidly deteriorating condition despite supportive therapy, the animal was euthanized 5 weeks after the manifestation of the signs. Severe decoloration of the affected musculature was evident at necropsy. No macroscopic evidence of tumor was noted in the spinal cord in the post-mortem examination.

The histopathological report of the muscle samples revealed severe muscle atrophy. Two anaplastic tumors were described in the spinal cord. One mass involved L4-L5 spinal cord segments, and the second involved S1-S2 spinal cord segments. The masses were described as large tumors which were replacing three-quarters of the parenchyma. They consisted of spindle cells forming bundles that intersected at various angles forming swirls and whorls (Figure 1). The abnormal cell population was characterized by highly pleomorphic, round nuclei with prominent nucleoli. Mitoses were numerous and atypical and giant nuclear forms and anaplastic cells were present (Figure 2). There was slight fibrous stroma and material resembling irregular nervous tissue throughout. Sections of the spinal cord proximal to the lesion consisted of areas of Wallerian degeneration with vacuolization of the white matter. The tumors were identified as anaplastic astrocytomas.

DISCUSSION

A recent study shows that canine astrocytomas are mostly diagnosed in the brain (85%), less commonly in the brain stem (10%), and least frequently in the spinal cord (3%). In previously reported cases, neoplasms were found in the thoracic portion of the cord (6). Different types of astrocytomas can be found according to the histological classification provided by the World Health Organization for tumors of the nervous system (10). We have found only one report of an anaplastic astrocytoma in the spinal cord of a dog (11), but we have not found any documentation of a multicentric astrocytoma of any kind in the canine spinal cord.

Signs seen in association with spinal cord tumors usually reflect the location of the neoplasm and are often indistinguishable from the signs caused by other transverse myelopathies at the same location (4). In this particular case, the unilateral nature of the problem suggested involvement of the central gray matter rather than of the peripheral white matter of the cord. This was supported by the absence of back pain over



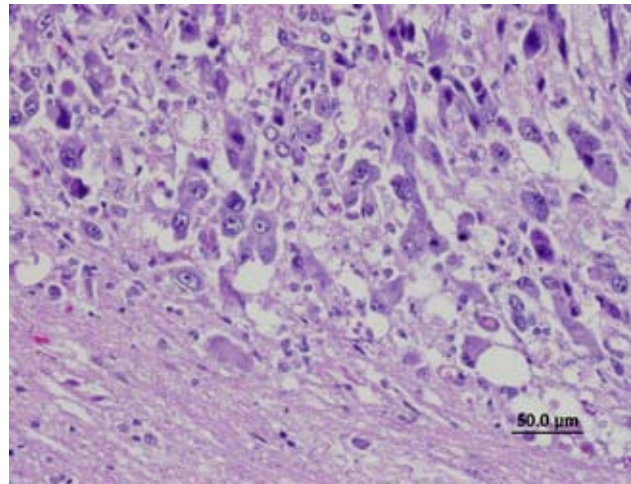
The masses were described as large tumors which were replacing three-quarters of the parenchyma.

Los tumores remplazaban tres cuartas partes del parénquima medular.

the compromised spinal segments. Even though this is a characteristic shared with spinal cord infarcts, dogs with spinal cord infarcts rarely worsen and usually show signs of recovery within 10 days (1). Further, the histopathological findings explain the lower motoneuron signs of the right side due to the destructive nature of the neoplasm arising from the gray matter and the upper motoneuron findings of the contralateral leg due, most likely, to compression of the left lateral tracts by the expanding intramedullary tumor. Plain radiographic abnormalities are uncommon with primary nervous system neoplasms (4), but some studies in human medicine have identified abnormalities, such as spondylosis or bone destruction, on plain radiographs in 20% of the patients in study (7). Advanced imaging would have been helpful in localizing the masses, specially the MRI which would have shown the architecture of the spinal cord. Contrast CT and/or myelography would have potentially shown compression at the tumor site if the expansion of the tumor was sufficient to prevent contrast distribution in the subdural space.

More common neoplasms of the spinal cord include meningiomas and oligodendrogliomas, as primary tumors, and hemangiosarcomas, as metastatic tumors. The proliferation of spiculated pleomorphic cells and the expansive nature of the tumors in this case along with the reactive glial cells were important in making the diagnosis. To further classify the nature and origin of these tumors, special immunostainings such as GFAP would have been not only interesting but also very helpful.

Although not very common, anaplastic astrocytomas, as well as other more common neoplasias should be considered as differential diagnosis in dogs with clinical signs similar to



Highly pleomorphic cells with round nuclei with prominent nucleoli. Numerous mitoses and atypical and giant nuclear forms and anaplastic cells were present.

Las células presentan alto grado de pleomorfismo con núcleos redondeados y nucléolo prominente. Mitosis numerosas y atípicas con células anaplásticas y núcleos gigantes.

those reported in this case. In the above described dog the particular neurological dysfunction and clinical progression were well correlated with the anatomical location of this uncommon tumor.

ACKNOWLEDGEMENTS

Barbara Powers, DVM, PhD, Diplomate American College of Veterinary Pathologists.

REFERENCES

- 1 Farnbach, GC. Spinal Cord Tumors, Spinal Cord Infarcts, and Degenerative Myelopathy. In: Newton CD (ed). Textbook of Small Animal Orthopedics. Publisher: International Veterinary Information Service (www.ivis.org), Ithaca, NY, 1985.
- 2 Mamom T, Meyer-Lindenberg M, Hewicker-Trautwein M, Baumgartner W. Oligodendroglioma in the Cervical Spinal Cord of a Dog. *Vet Pathol* 2004 (41):524-526
- 3 Braund KG. Neoplasia of the Nervous System. In: Clinical Neurology in Small Animals – Location, Diagnosis and Treatment. Publisher: International Veterinary Information Service (www.ivis.org), Ithaca, NY, 2003.
- 4 LeCouteur RA. Tumors of the Nervous System. In: Withrow S, MacEwen E (ed). Small Animal Clinical Oncology. Third Edition. W.B. Saunders Company. 2001; pp 514-521
- 5 Forterre F, Kaiser S, Matiasek K, Schmahl W, Brunberg L. Spinal cord canal tumor in dogs: 33 cases (retrospective study). *Kleintierpraxis*. 2002 (47):357-364
- 6 Stoica G, Kim H-T, Hall DG, Coated JR. Morphology, Immunohistochemistry, and Genetic Alterations in Dog Astrocytomas. *Vet Pathol* 2004 (41):10-19
- 7 Hausmann ON, Kirsch EC, Tolnay M, Gratzl O. Intramedullary spinal cord tumors: a clinical outcome and radiological follow-up study. *Swiss Med Wkly* 2001 (131):582-587

8 Bagley RS, Kornegay JN, Page RL, Thrall DE. Central Nervous System. In: Thrall DE (ed). Textbook of Small Animal Surgery. Second Edition, Volume 2. W.B. Saunders Company, 1993; pp 2137-2167

9 LeCouteur RA, Grandy JL. Diseases of the spinal cord. In: Ettinger S (ed) Textbook of Veterinary Internal Medicine. Fifth Edition, Volume 1. W.B. Saunders Company, 2000; pp 608-657

10 Kleihues P, Burger PC, Scheithauer BW. In: World Health Organization International Histological Classification of Tumours, 2nd ed. Springer-Verlag, Berlin, 1993; pp. 1-105

11 Zaki FA, Prata RG, Hurvitz AI, Kay WJ. Primary tumors of the spinal cord and meninges in six dogs. J Am Vet Med Assoc , 1975; 166 (5):511-517