

ISSN 1668-5466

Año 9 Volumen IX N° 2



CIENCIAS MORFOLÓGICAS

Publicación periódica de la Sociedad de Ciencias Morfológicas de la Plata

Diciembre 2007

CIENCIAS MORFOLÓGICAS

Revista de la Sociedad de Ciencias Morfológicas de La Plata
Publicación periódica de trabajos científicos del área de la Morfología

EDITOR CIENTÍFICO

Dr. Claudio Barbeito. Universidad Nacional de La Plata. CONICET. Argentina.

COMITÉ DE POLÍTICA EDITORIAL

Dra. Graciela Navone. Universidad Nacional de La Plata. CONICET. Argentina.

Dr. Mario Restelli. Universidad Nacional de La Plata. Argentina.

Dra. Susana Salceda. Universidad Nacional de La Plata. CIC. Argentina.

PhD Gustavo Zuccolilli. Universidad Nacional de La Plata. Argentina.

CONSEJO CIENTÍFICO EDITORIAL

Dra. María del Carmen Carda Batalla. Universidad de Valencia. España.

Dra. Ana Lía Errecalde. Universidad Nacional de La Plata. Argentina.

MSc Antonio Felipe. Universidad Nacional del Centro de la Provincia de Buenos Aires. Argentina.

Dra. María Teresa Ferrero. Universidad Nacional de Córdoba. Argentina.

MSc Stella Maris Galván. Universidad Nacional del Litoral. Argentina.

PhD Eduardo Gimeno. Universidad Nacional de La Plata. CONICET. Argentina.

Dra. María Elsa Gómez de Ferraris. Universidad Nacional de Córdoba. Argentina.

Dra. Alda González. Universidad Nacional de La Plata. CONICET. Argentina.

PhD Ben Hanelt. Universidad de Nebraska. Estados Unidos.

Dr. Daniel Lombardo. Universidad Nacional de Buenos Aires. Argentina.

Dra. Inés Martín Lacave. Universidad de Sevilla. España.

Dra. Marta Graciela Méndez. Universidad Nacional de La Plata. CONICET. Argentina.

Dr. Hugo Ortega. Universidad Nacional del Litoral. CONICET. Argentina.

Dr. Martí Pomarola. Universidad Autónoma de Barcelona. España.

Dr. Enrique Portiansky. Universidad Nacional de La Plata. CONICET. Argentina.

Dra. Sara Sánchez. Universidad Nacional de Tucumán. CONICET. Argentina.

PhD Andreas Schmidt-Rhaesa. Biekefeld. Alemania.

Dr. Eduardo Tonni. Universidad Nacional de La Plata. CIC. Argentina.

Dra. Irene von Lawzewitzch. Universidad Nacional de Buenos Aires. CONICET. Argentina.

Dr. Mauricio Zamponi. Universidad Nacional de Mar del Plata. CONICET. Argentina.

EDITOR ASOCIADO

MSc Norma González. Universidad Nacional de La Plata. Argentina.

Edición técnica y compaginación:

Méd. Vet. Pedro Fernando Andrés Laube. Universidad Nacional de La Plata. Argentina.

Propiedad: Sociedad de Ciencias Morfológicas de La Plata.

Sede: Facultad de Ciencias Veterinarias. Universidad Nacional de La Plata. Argentina.

Distribución: Sociedad de Ciencias Morfológicas de La Plata.

CIENCIAS MORFOLÓGICAS

Publicación periódica de la Sociedad de Ciencias Morfológicas de La Plata

Año 9, Vol. IX, Nº 2 - DICIEMBRE 2007

ÍNDICE

TRABAJOS ORIGINALES

Claudio G. BARBEITO; Vicente A. CATALANO; Norma V. GONZALEZ. CELL PROLIFERATION OF THE MOUSE SEBOCYTES IN SKIN AND PREPUTIAL GLAND	1-5
Antonio Eduardo FELIPE; Silvia Carmen GALLARRETA; Graciela MERINO. HABILIDADES DE VISUALIZACIÓN DE LOS ESTUDIANTES DE EMBRIOLOGÍA VETERINARIA	7-16

TRABAJO DE TESIS

Jorge M. GALOTTA LECTINHISTOQUÍMICA DEL EPITELIO INTESTINAL EN LOS MAMÍFEROS DOMÉSTICOS. ESTUDIO COMPARATIVO ENTRE EL EQUINO, EL CERDO Y EL CONEJO.....	17-21
RESÚMENES DEL IX CONGRESO y 6 ^{tas} JORNADAS DE EDUCACIÓN de la SOCIEDAD DE CIENCIAS MORFOLÓGICAS DE LA PLATA	23-72
ÍNDICE DE AUTORES	73-75
INSTRUCCIONES PARA LOS AUTORES	77-80

PRESENTACIÓN

La primera revista científica fue publicada en 1665 por la Royal Society de Londres; se trata de *Philosophical Transactions*, aun en vigencia. Desde entonces las publicaciones periódicas han sido uno de los medios fundamentales para que los científicos distribuyan sus descubrimientos y sus ideas. El sistema científico se ha hecho hoy mucho más exigente y en ocasiones parece perderse el sentido de la publicación científica como medio de difusión de ideas y conocimientos, y se constituye en una herramienta para demostrar producción y poder permanecer en el sistema. Se habla mucho de “*publicar o perecer*”, y quizás así se olvida que la publicación debe ser la consecuencia obvia de un trabajo realizado.

A lo anterior, en las últimas décadas se ha sumado la problemática de los sistemas de evaluación de las publicaciones. Existe un imperativo por publicar solo en revistas de alto impacto, y esto parece ser una regla excluyente; surge entonces un dilema: ¿cómo llega una revista a conseguir un buen índice de impacto si nadie publica en ella hasta que tenga ese valor? Las revistas nacionales se enfrentan en su mayoría con esta problemática. Ante esto cabe preguntarse si es importante apoyar a las publicaciones nacionales que brindan una alternativa para que los investigadores publiquen trabajos originales y revisiones. Numerosos miembros de la comunidad científica consideran una pérdida de tiempo escribir para revistas no incluidas en *PubMed* o cuyo impacto sea inferior a cierto valor. Pero quizás sea interesante bucear en la historia de la ciencia en la Argentina; así se revela que apellidos ilustres como el de los Premios Nobel Houssay y Leloir, junto al de sus discípulos y colaboradores, aparecen en artículos de las revistas internacionales más importantes, pero también en publicaciones nacionales de las que, en algunos casos, fueron inclusive fundadores. Quizás no debiéramos perder esa guía y considerar que la difusión de nuestros

trabajos en revistas nacionales lleva a que estas crezcan y que, en consecuencia, asimismo se contribuye al crecimiento de la ciencia en el nuestro país. Desde “Ciencias Morfológicas” creemos firmemente que las publicaciones nacionales, construidas con tanto esfuerzo, deben constituir un medio más de difusión de la producción científica argentina.

En la década de 1980 las revistas científicas impresas en papel enfrentan una crisis y es por ese momento que nacen las publicaciones electrónicas. La importancia de este formato de publicaciones se inicia en 1990 y se consolida definitivamente desde 1995. Es precisamente en el año 1995 que nuestra revista se publica por primera vez. Si bien la historia de “**Ciencias Morfológicas**” es breve, en tan corto tiempo ha experimentado los mismos cambios que *Philosophical Transactions* y tantísimas otras publicaciones de carácter científico han presenciado. La publicación de “**Ciencias Morfológicas**” en papel se extendió durante 11 años, lapso en el que podemos señalar que la revista, como publicación periódica de la Sociedad de Ciencias Morfológicas de La Plata, contó con el apoyo de los miembros de la Sociedad para cumplir con el objetivo de divulgar los resultados de las investigaciones desarrolladas en los marcos particulares que brindan las respectivas ciencias morfológicas. Asimismo, “**Ciencias Morfológicas**” no estuvo exenta de los alcances del incierto futuro que se señala para las publicaciones científicas.

En el año 2005, se recupera el anhelo de los primeros responsables de “**Ciencias Morfológicas**” y se modifican el formato de la revista, adecuándola a las normas editoriales estándar nacional e internacional. A esas modificaciones se agregan la inclusión de un Editor Científico y un Editor Asociado al tiempo que se incorporan investigadores de instituciones científicas y universidades nacionales y extranjeras a la gestión de evaluación de los trabajos. Asimismo se amplían los tipos de trabajos y se suma el inglés como idioma para la publicación.

El año 2007 marcó un punto de inflexión para “**Ciencias Morfológicas**”: haciendo

uso de la página de la Sociedad (www.scmlp.com.ar) el número correspondiente a agosto de ese año queda disponible para su consulta y descarga *on-line*. Consecuentemente, la revista se incorpora a la tendencia de mudar al formato electrónico, para hacer uso de las ventajas que ello implica, entre ellos la rapidez de publicación, la disponibilidad inmediata, la reducción de costos.

El presente número de “**Ciencias Morfológicas**” llega a sus lectores en el formato electrónico, esta vez bajo un nuevo número ISSN, reuniendo así un requisito que la revista alcanzó recién en el año 2005. En esta oportunidad se publican, en la primera sección dos trabajos de investigación. El primero de ellos está dedicado a la educación en ciencias morfológicas. El artículo lleva por título “**Habilidades de visualización de los estudiantes de Embriología Veterinaria**” (Felipe, AE, Gallarreta, SC y Merino, G: “*Visualization skills of students of Veterinary Embryology*”) y presenta resultados y reflexiones sobre un trabajo realizado en torno la utilización didáctica de imágenes. El segundo de los trabajos de investigación se titula “**Proliferación de los sebocitos del ratón en las glándulas cutáneas y prepuciales**” (Barbeito, CG, Catalano, VA y González, NV: “*Cell proliferation of the mouse sebocytes in skin and preputial gland*”).

En continuidad con números anteriores, la segunda sección incluye la publicación del resumen de una tesis en Ciencias Morfológicas. El resumen corresponde a la Tesis de Maestría en Anatomía y Fisiología Animal, realizada en la Universidad Nacional de Río Cuarto: “**Lectin histoquímica del epitelio intestinal en los mamíferos domésticos. Estudio comparativo entre el equino, el cerdo y el conejo.**” del M. V. Jorge M. Galotta.

La tercera y última sección de este número cuenta con los resúmenes en inglés de las comunicaciones presentadas en el IX Congreso y 6tas Jornadas de Educación de nuestra Sociedad, llevado a cabo los días 30 y 31 de agosto de 2007, en el que contáramos con una amplia representación de diversas disciplinas dentro de las Ciencias Morfológicas.

Como comentáramos más arriba, en su breve existencia, la revista ha contado con el apoyo de los miembros de la Sociedad; consideramos que ello se ve reflejado en las aportaciones de todos y cada uno de los autores en este nuevo número de “**Ciencias Morfológicas**”. Renovamos nuestro agradecimiento a los socios y autores como también la invitación a participar de este ámbito de difusión de los productos de investigación en el ámbito de las Ciencias Morfológicas.

Los editores

CELL PROLIFERATION OF THE MOUSE SEBOCYTES IN SKIN AND PREPUTIAL GLAND

Claudio Gustavo BARBEITO^{1,2}; Vicente Alberto CATALANO¹; Norma Viviana GONZALEZ³

¹Cátedra de Histología y Embriología, Facultad de Ciencias Veterinarias, Universidad Nacional de La Plata. Calles 60 y 118, La Plata, Argentina.

²Instituto de Patología, Facultad de Ciencias Veterinarias, Universidad Nacional de La Plata. Calles 60 y 118, La Plata, Argentina.

³Cátedra de Histología y Embriología Animal, Facultad de Ciencias Naturales y Museo, Universidad Nacional de La Plata. Calles 60 y 122, La Plata, Argentina.

Correspondence to: Barbeito, Claudio Gustavo.

Cátedra de Histología y Embriología, Facultad de Ciencias Veterinarias. UNLP. 60 y 118. La Plata (1900). Buenos Aires, Argentina.

E-mail: barbeito@fcv.unlp.edu.ar

Abstract. Preputial glands are specialized sebaceous gland of some rodent as mouse and rat. This gland is regulated by androgens and other hormones. In this work we analysed the mitotic activity of the alveolar and ductal cells of the mice preputial gland throughout a circadian period. The results were compared to data obtained from the skin sebaceous gland. The mitotic activity in the preputial sebocytes displayed a bimodal curve with the highest mitotic indices at 12:00 and 00:00 h while the lower values were reached at 20:00 and 08:00h. In the ductal cells, the mitotic activity showed a single mitotic peak at 12:00h and a trough at 20:00 h. In the sebocytes from skin glands, the acrophase was detected at 04:00 h. The average cell proliferation daily value was significantly higher in the preputial sebocytes when compared to cutaneous sebocytes. These results demonstrated the existence of quantitative and qualitative differences in the mitotic activity of the preputial gland sebocytes in relation to the skin sebocytes.

Keywords: cell proliferation, circadian rhythms, preputial glands, sebocytes.

INTRODUCTION

Preputial glands are alveolar complex holocrine glands; they are accessory to the male reproductive tract of some rodents, as the rat and the mouse. Due to its pheromones content, their products have been assigned functions related to territorial and sexual behavioral activities (11, 32). These glands' size and activities are larger in domineering aggressive males and their secretion is attractive to females (10, 11, 31). In addition, Marchlewska-Koj *et al.* (1990) found that the presence of these glands' extract induces estrous in virgin female mice.

Their main cellular type is the alveolar cell, mostly referred as sebocyte. Electron microscopy shows that the rat preputial gland resembles the human sebaceous gland, not only in terms of containing a sebocyte-like population of cells in an acinar arrangement at different maturational

stages, but also in the morphology of its organelles (17). In these sense, preputial glands resemble the sebaceous skin glands and can be considered a specialization of these last. Accordingly, the preputial glands have been employed as an experimental model to study sebocytes growth and differentiation (27, 30).

Several hormones are known to influence these glands' activities (9). Insulin-like growth factor 1(IGF-I) and insulin, but not growth hormone (GH), stimulate *in vitro* cell proliferation of the glands. GH enhances preputial sebocytes differentiation (6). On the other hand, androgens have been found to stimulate preputial gland sebocytes as well as skin sebocytes (7, 13, 21, 24, 30).

Some hormones related to the preputial glands proliferation in the mouse exhibit daily variations as reported for androgens and insulin plasma levels (15, 23, 29). In addition, many cell

populations in the adult mouse exhibit a daily proliferation rhythm (2, 8, 25).

For a better understanding of the preputial cell proliferation, the following study was carried out to: 1) characterize its temporal structure in adult mice, and 2) to compare preputial and sebaceous skin glands cell proliferation.

MATERIALS AND METHODS

Forty-two male C3H/Avy strain mice, five month-old were used. Animals were housed under standardized conditions for a 24 h periodicity analysis in an ad hoc room with a $22 \pm 2^\circ\text{C}$ temperature and lighting regimen of 12 h light - 12 h darkness (lights on 06.00-18.00 h). Pelleted food and water were provided ad libitum. Mice were divided into 6 lots (n: 6-8) for killing by decapitation and exsanguination at the following times of day: 00:00, 04:00, 08:00, 12:00, 16:00, and 20:00 h. Each mouse received an intraperitoneal colchicine dose of $2 \mu\text{g/g}$ body weight 4 h before sacrifice.

Preputial glands and a sample of auricular skin from each animal were fixed in 10% buffered formalin. The embedding was performed in paraffin. Five μm -thick sections were stained with H&E.

The observation was carried out under immersion oil objective (1000x). In the preputial glands, two cell-populations were monitored: alveolar cells (preputial sebocytes, PS) from the basal and parabasal layers and ductal cells (DC). No less than 3000 PS and 1500 DC per individual were monitored scoring mitosis along with the total number of cell nuclei every tenth field. In the cutaneous glands, the same procedure was employed for 3000 alveolar cells (cutaneous sebocytes, CS).

The mitotic index (colchicine metaphase/1000 nuclei) (MI) for each animal and cell-type was calculated from data collected. Using these individual data, the arithmetic mean \pm standard error from each lot and group was assessed. The significance of the differences

between organs, lots and groups was analyzed by Anova and Student's t-test.

RESULTS

Table 1 and Figure 1 summarize the results on mitotic activity in PS, DC and CS. The mitotic activity in the PS presented important variations in the different time-points, displaying a bimodal curve (Figure 1) with the highest mitotic indices at 12:00 and 00:00 h while the lower values are reached at 20:00 and 08:00h (Table 1). In DC, the mitotic activity showed a single mitotic peak at 12:00 h and a trough at 20:00 h (Figure 1 and Table 1). For CS the acrophase was detected at 04:00 h (Figure 1 and Table 1).

The average cell proliferation daily value was significantly higher in PS (7.93 ± 0.68) when compared to CS (5.6 ± 0.3) (Table 1).

DISCUSSION

Both cell-populations from the mouse preputial glands under study presented mitotic daily variations. Our results demonstrated clear-cut qualitative and quantitative differences in the proliferation of PS and DC.

DC showed a higher mitotic activity than PS. This finding is in agreement with higher proliferation indices reported for ductal cells in other exocrine glands as the submaxillary gland (1). Moreover, whereas DC mitotic activity presented a single peak curve, PS had a different rhythmicity for the mitotic daily curve showed a bimodal characteristic. Similar circadian bimodal rhythms have been found in other mouse cell-populations (2, 25). For instance, the pars intermedia in female mice displays a comparable temporal structure at 28 d of age for two mitotic peaks are found at midnight and noon, whereas in adult females the mitotic daily curve is still bimodal but peaks are found at 04:00 and 16.00 h (2).

The mitotic index values were significantly higher in PS than in CS. Furthermore, the daily

mitotic curve's structure for PS revealed a bimodal pattern whereas CS curve displayed a single peak.

Socially dominant male mice have larger preputial glands than do subordinate males (4). A similar situation has been observed in rats for dominant individuals that had heavier preputial glands compared to subordinate and subordinate rats (20). Accordingly to their sexually-related role, PS are stimulated to proliferate and differentiate by androgen (13, 14, 18) as in other sebaceous glands, namely CS. As both PS and CS possess receptors for androgen and other hormones as the melanocortin 5 (26), the effect of these signals should not be considered as a cause to explain differences concerning PS and CS mitotic activity. Results from the present study suggest a paracrine and autocrine control hypothesis on the preputial gland proliferation and also the existence of differences in regard to skin sebaceous glands.

Differential organ response to the androgens' effects on cell-cycle were previously reported (28); these variations could be related to the presence of different enzymes isotypes that catalyze the conversion of sexual steroids in the PS and in CS (5). Another plausible explanation would be a differential enzymatic activity (3, 19).

The preputial glands of several rodents' species have been long employed as a model to investigate a wide spectrum of topics e.g. the rat preputial system is used as an experimental model in sebaceous gland physiology (26). More recently, preputial glands have been used in numerous assessments on toxicological aspects (12, 22), and sex, individuality, and/or the genetic background differences between mice strains (32). Our work strongly suggests that the extrapolation of PS findings to CS may lead to erroneous interpretations. The existence of circadian rhythms in these glands could be extended to other aspects of the organs'

Figure 1

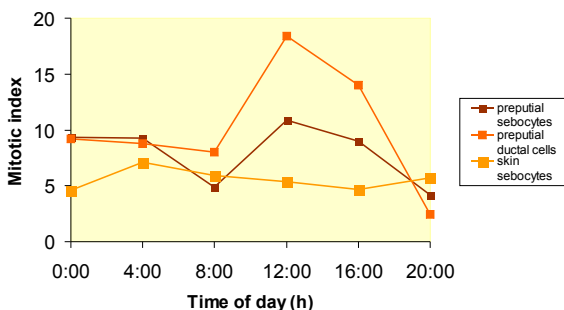


Table 1. Mitotic activity of preputial glands and sebaceous skin

Hour	Mitotic index			P
	Preputial sebocytes (A)	Preputial ductal cells (B)	Skin sebocytes (C)	
0:00	9.33 ± 1.71	9.18 ± 0.79	4.6 ± 0.60	
4:00	9.27 ± 2.01	8.75 ± 1.75	7.1 ± 0.50	
8:00	4.91 ± 0.92	8.04 ± 2.16	5.9 ± 0.50	
12:00	10.88 ± 2.29	18.39 ± 3.05	5.4 ± 0.70	
16:00	9.02 ± 1.01	13.98 ± 2.03	4.7 ± 0.79	
20:00	4.16 ± 0.80	2.47 ± 0.62	5.7 ± 1.00	
X 24 h	7.93 ± 0.68	10.19 ± 1.07	5.60 ± 0.30	A-B < 0.01; B-C < 0.05
P	00:00 - 20:00 < 0.05	12:00 - 20:00 < 0.001	00:00 - 04:00 < 0.01	
	08:00 - 16:00 < 0.05			
	20:00 - 12:00 < 0.05			

a Results are expressed as mean ± standard error

X 24 h: mean of the whole sample period; P: significance of differences in mean values.

REFERENCES

1. Barbeito CG, García MN, Savignone CA, Catalano VA, Flamini MA, Badrán AF, Moreno FR. (1997). Actividad mitótica de los epitelios de epidermis, lengua, túbulos contorneados renales y conductos de la glándula submaxilar del ratón portador del tumor SSIK. *Ciencias Morfológicas*; 3: 9-18.
2. Barbeito CG, Surur JM, Badrán AF. (2000). Mitotic activity of the pars intermedia in the female mouse: age-associated variations in proliferation rate and circadian periodicity. *Chronobiol Int*; 17:751-756.
3. Blanchard PG, Luu-The V. (2007). Differential androgen and estrogen substrates specificity in the mouse and primates type 12 17 beta-hydroxysteroid dehydrogenase. *J Endocrinol*; 194:449-455.
4. Bronson FH, Marsden, HM. (1973). The preputial gland as an indicator of social dominance in male mice. *Behav Biol*; 9:625-628.
5. Deplewski D, Liao S, Rosenfield RL. (1997). Preputial sebocyte 5alpha-reductase isoform specificity. *Endocrinol*; 138:4416-4420.
6. Deplewski D, Rosenfield R. (1999). Growth hormone and insulin-like growth factors have different effects on sebaceous cell growth and differentiation. *Endocrinol*; 140:4089-4094.
7. Ebling FJ, Ebling E, Randall V, Skinner J. (1975). The effects of hypophysectomy and of bovine growth hormone on the responses to testosterone of prostate, preputial, Harderian and lachrymal glands and of brown adipose tissue in the rat. *J Endocrinol*; 66:401-406.
8. García MN, Barbeito CG, Andriani LB, Badrán AF. (2001). Circadian rhythm of the DNA synthesis and the mitotic activity of tongue keratinocytes. *Cell Biol Int*; 25:179-183.
9. Hay JB, Meddis D, Thody AJ, Shuster S. (1982). Mechanism of action of alpha-melanocyte-stimulating hormone in rat preputial glands: the role of androgen metabolism. *J Endocrinol*; 94:289-294.
10. Hayashi S. (1989). Male mice: Social Dominance Influenced by Strange Male Odors. *Aggress Behav*; 15:1-3.
11. Hayashi S. (1990). Social Condition Influences Sexual Attractiveness of Dominant Male Mice. *Zool. Sci*; 7: 889-894.
12. Homady M, Hussein H, Jiries A, Mahasneh A, Al-Nasir F, Khleifat K. (2002). Survey of Some Heavy Metals in Sediments from Vehicular Service Stations in Jordan and Their Effects on Social Aggression in Prepubertal Male Mice. *Environmental Res*; 89:43-49.
13. Huggins C, Parson FM, Jensen EV. (1955). Promotion and growth of preputial glands by steroids and the pituitary growth hormone. *Endocrinol*; 57:25-52.
14. Labrie F, Luu-The V, Martel C, Chernomoretz A, Calvo E, Morissette J, Labrie C. (2006). Dehydroepiandrosterone (DHEA) is an anabolic steroid like dihydrotestosterone (DHT), the most potent natural androgen, and tetrahydrogestrinone (THG). *J Steroid Biochem Mol Biol*; 100:52-58.
15. Lucas LA, Eleftheriou BE. (1980). Circadian variation in concentrations of testosterone in the plasma of male mice: a difference between BALB/cBy and C57BL/6By inbred strains. *J Endocrinol*; 87:37-46.
16. Marchlewska-Koj A, Pochron E, Sliwowska A. (1990). Salivary glands and preputial glands of males as source of estrus-stimulating pheromone in female mice. *J Chem Ecol*; 16: 2817-2822.
17. Mednieks MI, Laurent SJ, Hand AR, Rosenfield RL. (1991). Cyclic AMP-receptor protein activity in rat preputial cells. *J Inv Dermatol*; 97: 517523.
18. Miyake K, Ciletti N, Liao S, Rosenfield RL. (1994). Androgen receptor expression in the preputial gland and its sebocytes. *J Inv Derm*; 103, 721725.
19. Pelletier G, Luu-The V, Li S, Labrie F. 2005. Localization of type 8 17beta-hydroxysteroid dehydrogenase mRNA in mouse tissues as studied by in situ hybridization. *J Histochem Cytochem*; 53:1257-1271.
20. Pohorecky LA, Blakley GG, Ma EW, Soini HA, Wiesler D, Bruce KE, Novotny MV. (2008). Social housing influences the composition of volatile compounds in the preputial glands of male rats. *Hormones Behav*; 53:536-545.
21. Potter JE, Prutkin L, Wheatley VR. (1979). Sebaceous gland differentiation. I. Separation, morphology and lipogenesis of isolated cells from the mouse preputial gland tumor. *J Invest Dermatol*; 72:120-127.
22. Rawdah K Al-Thani, Aisha S. Al-Thani, Elbetieha, A, Darmani H. (2003). Assessment of reproductive and fertility effects of amitraz pesticide in male mice. *Toxicol Letters*; 138:253-260.
23. Sayegh JF, Kobar G, Lajtha A, Vadasz C. (1990). Effects of social isolation and the time of day on testosterone levels in plasma of C57BL/6By and BALB/cBy mice. *Steroids*; 55:79-82.
24. Sherins RJ, Bardin CW. (1971). Preputial gland growth and protein synthesis in the androgen-insensitive male pseudohermaphroditic rat. *Endocrinol*; 89:835-841.

25. Surur JM, Catalano VA, Flamini MA, Barbeito CG. (2005). Effects of tumors on the daily mitotic activity of mouse *pars intermedia*. *Cell Biol Int*; 29: 173-155.
26. Thiboutot D, Sivarajah A, Gilliland K, Cong Z, Clawson GJ. (2000). The melanocortin 5 receptor is expressed in human sebaceous glands and rat preputial cells. *Invest Dermatol*; 115:614-619.
27. Thody AJ, Shuster S. (1973). Possible role of MSH in the mammal. *Nature*; 245: 207-208,
28. Tsai TH, Scheving LE, Scheving LA, Pauly JE. (1985). Sex differences in circadian rhythms of several variables in lymphoreticular organs, liver, kidney, and corneal epithelium in adult CD2F1 mice. *Anat Rec*; 211:263-270.
29. Weinert D, Ulrich FE, Schuh J. (1987). Ontogenetic changes in the circadian rhythm of plasma insulin and its correlation to food intake. *Biomed Biochim Acta*; 46:387-395.
30. Wheatley VR, Potter JE, Lew G. (1979). Sebaceous gland differentiation: II. The isolation, separation and characterization of cells from the mouse preputial gland. *J Invest Dermatol*; 73:291-296.
31. Yamashita J, Hayashi S, Hirata Y. (1989). Reduced size of preputial glands and absence of aggressive behavior in the genetically obese (Ob/Ob) mouse. *Zool Sci*; 6:1033-1036.
32. Zhang JX, Rao XP, Sun L, Zhao CH, Qin XW. (2007). Putative chemical signals about sex, individuality, and genetic background in the preputial gland and urine of the house mouse (*Mus musculus*). *Chem Senses*; 32:293-303.

ACKNOWLEDGEMENTS

The authors wish to thank PhD Eduardo Gimeno for the critical reading of the manuscript. This work was supported with grants from National University of La Plata. Thanks are due to Mr. Ruben Mario and Ms. Paula Dumont for their technical assistance.

HABILIDADES DE VISUALIZACIÓN DE LOS ESTUDIANTES DE EMBRIOLOGÍA VETERINARIA

VISUALIZATION SKILLS OF STUDENTS OF VETERINARY EMBRYOLOGY

Antonio Eduardo FELIPE¹; Silvia Carmen GALLARRETA¹; Graciela MERINO²

¹Depto. Cs. Biológicas, Fac. Cs. Veterinarias, UNCPBA, Campus Universitario (B7000GHG) Tandil; ²UNLP; Buenos Aires, República Argentina.

Dirección postal: J. Hernández 353, (B7000GHG) Tandil, TE: 0291-449332.

E-mail: afelipe@vet.unicen.edu.ar

Resumen. Las representaciones científicas son imágenes visuales que pueden ser decodificadas, interpretadas y valoradas en sus alcances y limitaciones. El propósito de este estudio fue caracterizar las habilidades de visualización de estudiantes de embriología utilizando representaciones gráficas. Se trabajó con 32 estudiantes universitarios voluntarios del primer año de Ciencias Veterinarias. Se efectuaron dos series de entrevistas. La primera, con la totalidad de los estudiantes, se centró en la indagación de nociones sobre términos relacionados con las habilidades de visualización. En la segunda serie, 12 estudiantes resolvieron instrumentos de visualización, orientación y relaciones espaciales. Los estudiantes calificaron a las tareas como de alta dificultad por su falta de hábitos en el trabajo con imágenes, reconociendo que hacían uso de las mismas sólo para distraerse o por obligación. La mayoría de los estudiantes (83,3%) señaló que habían elaborado representaciones ante las exigencias de sus docentes. La mayoría de los estudiantes (58%) resolvió al menos la mitad de las rotaciones solicitadas. El rango de respuestas correctas en el establecimiento de relaciones espaciales fue del 50 al 92%. En conclusión, la mayoría de los estudiantes carecía de experiencia en la utilización didáctica de imágenes, mostrando deficiencias en las habilidades de visualización.

Palabras clave: visualización, estudiantes, embriología.

Abstract. Scientific representations are visual images that count on referring concepts and can be decodified, interpreted and valued. The aim of the present study was to characterize the visualization skills of students of veterinary embryology using graphic representations. Thirty two first year Veterinary Sciences voluntary students were interviewed in two occasions. First interview included all students and assessed their knowledge about terminology related with visualization skills. Twelve students participated in the second interview which was based on the resolution of instruments of spatial visualization, spatial orientation and spatial relationships. Student's opinion was that the work was very difficult. This could be explained for their inexperience in working with images; moreover they recognized that they had just used them for entertainment or obligation. The majority of interviewees (83.3%) expressed they had previously made representations only to fulfill teacher's requirements. Fifty eight percent of students were able to resolve at least half of the rotations. In regard to the ability to establish spatial relations, the range of right answers was 50 to 92%. It can be concluded that most of the students lacked experience in the didactic use of images, showing deficiencies in their visualization skills.

INTRODUCCIÓN

La memoria a largo plazo ha sido considerada como la capacidad, siempre mejorable, de registrar, retener y recordar conceptos, hechos, fenómenos y relaciones. La mejora de este tipo de memoria se basa en la utilización eficiente de estrategias y técnicas, las cuales se centran en tres mecanismos básicos: la asociación, la categorización y la visualización. En este trabajo

nos ocupamos de la visualización, entendida fundamentalmente como la capacidad para “ver mentalmente”, para representar en la imaginación un objeto concreto y dotarlo de un color, tamaño, forma y características definidos. El término *visualización* se emplea para referirse a las actividades de imaginación visual y se extiende en su uso para aplicarlo a la creación de imágenes externas que permiten expandir la

experiencia visual o imaginación (1, 2, 3). Numerosos avances científicos parecen deberse a la capacidad de visualización (4).

Diferentes autores han señalado que la esencia de la creatividad científica está asociada con la imaginación visual, metafórica y temática, concibiendo a los científicos como pensadores y comunicadores visuales (4, 5, 6). Mathewson (6) destaca que *“Los fenómenos y procedimientos de la ciencia y la tecnología son visuales, analógicos y temáticos. Basados en estas características, el núcleo visual de la ciencia puede ser descrito en términos de imágenes maestras (master images) en el contenido de la ciencia y procesos visuales en la práctica de la ciencia”* (p. 529).

Muchas de las representaciones científicas son consideradas como imágenes visuales (diagramas, esquemas, microfotografías, imágenes digitalizadas, ecografías, etc.) que, en alguna etapa de su elaboración, contaron con una mediación instrumental o tecnológica. Tales representaciones disponen de un concepto científico que actúa como referente y pueden ser decodificadas por los expertos, interpretadas y valoradas en sus alcances y limitaciones. Entre estas últimas, la distancia entre la reconstrucción visual del concepto referente y su representación. En cambio, los alumnos pueden aceptar como verdaderas a tales representaciones, sin contemplar la mediación instrumental existente (7). Prendes Espinosa (8) conceptualiza a las imágenes externas como representaciones de la realidad, sin necesidad de mantener relación de semejanza con ella, que se constituyen con lenguaje y códigos particulares. De esta forma, las imágenes pueden ser susceptibles de diferente lectura y análisis, como se señaló, entre expertos y novatos. Cabe considerar aquí que los expertos poseen una red compleja de representaciones de distintos órdenes y que pueden moverse en esa red con facilidad, pudiendo cambiar de modelo en base a la actividad que desarrollan. Esto se basa en que poseen los conocimientos de las hipótesis teóricas que establecen nexos entre el modelo y la realidad modelizada (7). Esta amplia capacidad

de moverse entre los modos y niveles de representación, no puede atribuirse, de manera automática, a los estudiantes. Varias investigaciones han demostrado la complejidad que presenta la habilidad para moverse entre modos y submodos de representación. Recordemos que esta habilidad es central para el logro de una completa comprensión de los modelos científicos. La información contenida en las imágenes se procesa de un modo diferente a la contenida en un texto. Por otra parte, las imágenes poseen un contenido informativo polisémico, dificultando predecir la o las posibles interpretaciones que puede realizar un sujeto de una imagen dada (9).

Así como en el terreno de la ciencia la capacidad de visualización es considerada relevante en la producción de nuevos conocimientos, en el ámbito educativo resulta importante el desarrollo de habilidades de alfabetización visual, estrechamente relacionadas con la capacidad de visualización. Barnea (10) establece tres habilidades (aplicables a todos los modos de representación) en orden ascendente de importancia: a.- visualización espacial: habilidad para entender con precisión objetos tridimensionales desde sus representaciones bidimensionales; b.- orientación espacial: habilidad para imaginar cómo se verá una representación desde una perspectiva diferente; y c.- relaciones espaciales: habilidad de visualizar el efecto de operaciones como rotación, reflexión e inversión, o para manipular objetos mentalmente.

En el caso particular de la enseñanza de contenidos embriológicos, las imágenes utilizadas requieren del establecimiento de relaciones topológicas. Estas son internas dentro de una figura u objeto, o constituyen relaciones bicontinuas simples entre dos o más figuras. Tales relaciones se construyen cuando el espacio se percibe como relaciones de proximidad y separación, continuidad y sucesión, interioridad, exterioridad y contorno. Dada su particular complejidad y el constante uso que se hace de las imágenes en la enseñanza de la embriología, el

propósito de este estudio fue caracterizar la capacidad de visualización de estudiantes de esa disciplina utilizando representaciones gráficas (imágenes pictóricas concretas).

METODOLOGÍA

Muestra: se trabajó con 32 estudiantes del segundo cuatrimestre del primer año de Ciencias Veterinarias que habían aprobado el Curso de Histología, Embriología y Teratología. Los estudiantes fueron notificados de los fines del trabajo y participaron voluntariamente.

Contexto de trabajo: se utilizaron los mismos espacios físicos destinados a las actividades prácticas del Curso, efectuándose entrevistas individuales fuera de las actividades curriculares habituales.

Fases e instrumentos de trabajo: El trabajo se organizó en dos series de entrevistas individuales. La primera abarcó a la totalidad de

la muestra y se centró en la indagación de sus nociones sobre términos relacionados con las habilidades de visualización. Para ello se elaboró una entrevista semiestructurada centrada en los conceptos de posiciones en el espacio, rotación, eje de rotación, inversión, grados de rotación y relaciones entre componentes de un objeto (ver Anexo 1). Durante el trabajo, se les solicitó a los estudiantes la realización de esquematizaciones libres que ejemplificaran algunos de esos conceptos.

En la segunda serie de entrevistas, se trabajó con 12 participantes seleccionados al azar. Para estas entrevistas, a fin de evaluar la capacidad de visualización de los estudiantes, se elaboraron tres instrumentos de resolución individual, uno para cada habilidad implicada (visualización espacial, orientación espacial y relaciones espaciales) (Cuadro 1 y Anexo 2).

Instrumento - Habilidad	Descripción	Puntaje
1.- Visualización espacial	a.- Dada una representación bidimensional los estudiantes debían describir (en formas oral y escrita) y esquematizar cómo sería el objeto en su vista tridimensional. Objeto: diagrama de embrión mamífero en estadio de gástrula con dos de sus anexos (amnios y saco vitelino).	- descripción oral adecuada y completa: 1 punto. - descripción oral adecuada e incompleta: 0.5 punto. - descripción escrita adecuada y completa: 1 punto. - descripción escrita adecuada e incompleta: 1 punto. - esquematización adecuada: 1 punto. (total: 3 puntos)
	b.- Dadas representaciones bidimensionales seriadas de embriones con sus anexos, los estudiantes debían seleccionar la opción correcta de cada uno de los cuatro conjuntos de afirmaciones dadas.	- 1 punto por cada acierto (total 4 puntos).
2.- Orientación espacial	Dadas representaciones bidimensionales yseudotridimensionales los estudiantes debían describir cómo se vería el objeto si se rotara 45° y 90° a la derecha. Objetos: blastocisto mamífero y feto de ratón de 15 días de gestación.	- 1 punto por cada acierto (total 8 puntos).
	Se muestra un objeto en dos posiciones diferentes, que representan sendas rotaciones según los ejes X, Y- o Z-. Los estudiantes deben seleccionar de una serie de imágenes dadas, el objeto cuya posición representa la siguiente rotación en el patrón establecido. Objetos: esquemas del desarrollo del páncreas y del encefalo.	- 1 punto por cada acierto (total 2 puntos).
3.- Relaciones espaciales	Dadas representaciones bidimensionales los estudiantes debían describir cómo se vería el objeto si fuera observado "desde arriba", "desde abajo" y "desde adentro". Objeto: discoblástula.	- 1 punto por cada acierto (total 3 puntos)

Cuadro 1. Instrumentos elaborados para evaluar la capacidad de visualización de los estudiantes.

En todos los casos se utilizaron imágenes concretas pictóricas. Estas fueron seleccionadas de manera tal que presentaran el menor número de detalles secundarios a fin de que estos no obraran como obstáculos para la comprensión de los alumnos. Cada elemento representado en las figuras estaba identificado con una letra y se aclaró a los estudiantes que no se requería de la denominación científica de los componentes.

Durante las entrevistas de la segunda serie, al enfrentar a los estudiantes con las primeras representaciones gráficas, se les pidió que enunciaran en voz alta su manera de analizar las imágenes. Para ello se les formularon preguntas orientadoras del tipo: “¿Qué haces para analizar la imagen?, ¿En qué piensas?, ¿Qué tienes en cuenta al mirarla?, ¿Cómo la analizas?” En forma complementaria, se solicitó a los estudiantes que calificaran cada una de las tareas por su grado de dificultad (alta, media, baja o nula) y se les pidió que justificasen su valoración.

Análisis: La puntuación para cada uno de los participantes se determinó por la sumatoria de respuestas correctas y calculando el porcentaje sobre el puntaje total (20 puntos). Se asumió que con un porcentaje igual o superior al 80%, la capacidad de visualización era alta, en tanto que valores ubicados entre 79 y 60%, 59 y 40% y 39% o menos era media, baja o muy baja, respectivamente.

Para el análisis de algunas respuestas se consideraron alternativas factibles cuando los estudiantes desconocían la conformación tridimensional real. Por ejemplo, en el caso del instrumento 1 en el cual dada una representación bidimensional, los estudiantes debían describir y esquematizar el objeto en su vista tridimensional, podían concebir que se trataba de un corte transversal de una estructura esférica o cilíndrica y dar respuestas que, aunque no fueran correctas desde el punto de vista del conocimiento científico, fueran coherentes con la información que se podía inferir del análisis de la imagen.

RESULTADOS

Entrevistas sobre términos relacionados con la capacidad de visualización

Todos los estudiantes definieron a la rotación de un objeto utilizando términos asociados con la posibilidad de que el mismo “gire” o “de vueltas” en el espacio. Se identificaron dificultades al tratar la existencia de ejes de rotación, por cuanto, un 62,5% de los entrevistados no habían considerado la posibilidad de existencia de tales ejes. Asociaban los mismos con sus estudios previos en el nivel secundario con los ejes de la Tierra, pero no con una estructura biológica como un embrión preimplantacional (mórula, blastocisto, gástrula, etc.). Un 31,3% de los participantes habló de los ejes de simetría de la gástrula e hizo referencia a la notocorda, pero no pudo elaborar descripciones o explicaciones al respecto. Esto es, reconocían la existencia de un “eje” y lo ejemplificaban sin poder precisar el significado del concepto. Otro porcentaje similar al anterior, señaló los planos de simetría o de corte, en referencia a sus estudios de anatomía, pero destacó que nunca imaginaron que para un embrión se pudieran considerar ejes.

La noción de inversión fue definida tautológicamente por la mayoría (68,8%) como que “algo se invierte” o “se da vuelta” (50%). Un 46,8% confundió el término con eversión (sin utilizar este) al sostener que imaginaban la inversión como “que algo de adentro sale afuera”. Un 71,8% de los estudiantes sólo conocía el término desde el punto de vista económico (“invertir plata”) o “invertir tiempo” y señaló que nunca lo aplicarían a un objeto biológico.

Al trabajar sobre las relaciones entre componentes de un objeto, fue necesario explicarles al 75% de los estudiantes, en qué consistía la descripción de un objeto. Para ello se recurrió a solicitarles que respondieran a la pregunta “Si tuvieras que describir la mesa que tienes frente a vos, ¿qué dirías?”

En cuanto a las esquematizaciones, todos los estudiantes recurrieron a la representación de

objetos cotidianos y que tenían a su alcance, como lapiceras, carpetas y teléfonos celulares. El 62,5% de los entrevistados elaboró dibujos sin manipular los objetos, en tanto que un 25% manifestó la necesidad de mover los objetos (rotarlos), antes de representarlos. Los restantes estudiantes (12,5%) no pudieron elaborar representaciones.

Entrevistas sobre habilidades de visualización

La mayoría de los estudiantes (75%) calificaron a las tareas presentadas durante las entrevistas sobre visualizaciones como “dificultosas” o “muy dificultosas”. Atribuyeron su valoración a la falta de hábitos en el trabajo con imágenes, reconociendo que hacían uso de las mismas sólo como elementos para distraerse durante las lecturas de los textos o por obligación, cuando alguna tarea les requería su análisis en las

actividades prácticas. Un alto porcentaje de los estudiantes (83,3%) señaló que sólo habían elaborado representaciones gráficas para cumplir con las exigencias de sus docentes.

En cuanto a sus expresiones sobre la manera en que analizaban las imágenes, la mayoría de ellos (58,3%) sólo consideraban el aspecto general, dejando de lado los detalles; se centran en describir a partir de los contornos o límites y no otorgaban importancia al tamaño diferente de los componentes representados.

Sólo dos estudiantes mostraron una capacidad de visualización considerada como alta, en tanto que tres fueron categorizados como de capacidad media, cuatro como baja y tres como muy baja. Para cada habilidad implicada se obtuvieron valores similares. En la Tabla 1 se muestran los porcentajes de respuestas correctas por estudiante.

Estudiante	Habilidades		
	1.- Visualización espacial	2.- Orientación espacial	3.- Relaciones espaciales
1	100	100	100
2	42.8	16.6	66.7
3	42.8	33.3	66.7
4	57.1	16.6	33.3
5	28.6	33.3	66.7
6	100	50	100
7	92.9	66.7	33.3
8	42.8	33.3	100
9	42.8	50	33.3
10	7	100	66.7
11	64.3	66.7	33.3
12	28.6	50	33.3

Tabla 1. Respuestas correctas por estudiante (valores expresados en porcentajes).

Habilidad de visualización espacial: La mayoría de los estudiantes describieron de manera adecuada pero incompleta, tanto en forma oral (58%) como escrita (67%), la representación bidimensional de un embrión mamífero en estadio de gástrula con el amnios y el saco vitelino (fig. 1). Pero sólo el 41,6% de los entrevistados pudo elaborar un esquemaseudotrídimensional completo. Tres estudiantes hicieron sus descripciones orales y escritas de manera ordenada, es decir, considerando uno o más puntos de referencia. En cuanto a la selección de afirmaciones correctas a partir del análisis de esquemas seriados, se analizaron los errores cometidos junto con los estudiantes. Las causas atribuidas a los mismos se centraron en dificultades para identificar elementos representados cuando estos variaban




Figura 1. Esquemas secuenciados de embrión mamífero en estadio de gástrula con dos de sus anexos. El estudiante describió el aspecto tridimensional del objeto

en su posición o tamaño.

Habilidad de orientación espacial: la mayoría de los estudiantes (58%) resolvió al menos el 50% de las rotaciones solicitadas; sin embargo, sólo un 16.7 % de ellos (2 de 12) acertó todas las opciones (fig. 2). En cuanto a la identificación de la representación de un objeto sobre la base de un patrón según los ejes X-, Y- o Z-, numerosos estudiantes (58,3%) presentaron dificultades para resolver la




Figura 2. Tres representaciones elaboradas por diferentes estudiantes para la actividad de orientación espacial rotando un blastocisto.

actividad.

Habilidad para establecer relaciones espaciales: en cuanto a describir cómo se vería el objeto (discoblástula) si fuera observado “desde arriba”, el 92% de los estudiantes lo hizo correctamente. El 66,6% de los participantes

describió correctamente una vista “desde abajo” del objeto. En ambos casos, sus justificaciones permitieron asumir que presuponían la existencia de un patrón de continuidad de los elementos representados. Las mayores

dificultades se presentaron al describir el objeto “desde adentro”. Un 50% de los estudiantes lo hizo incorrectamente, en general al no considerar en su descripción parte de las estructuras representadas. Por ejemplo, no atribuían entidad

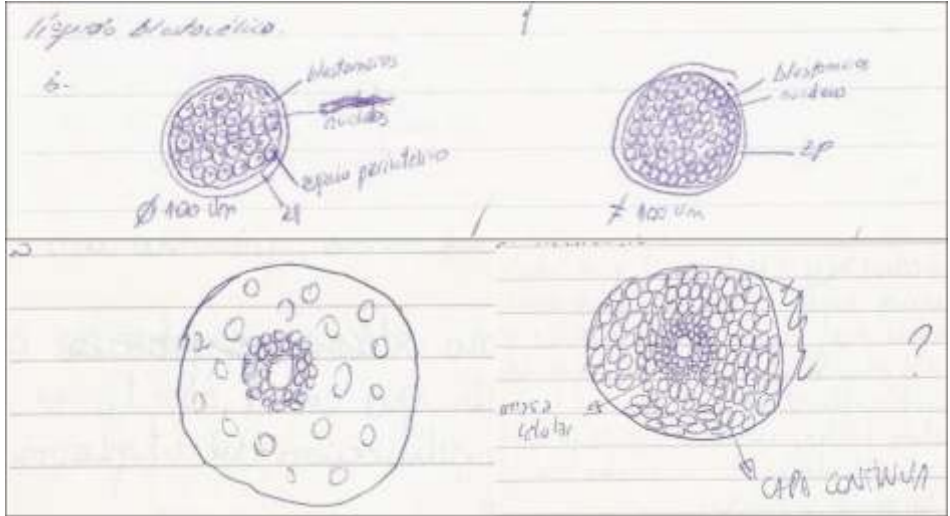


Figura 3. Representaciones elaboradas por dos estudiantes sobre las relaciones espaciales en la discoblástula.

al vitelo o al blastocelo (fig. 3).

DISCUSIÓN

La visualización es considerada como una competencia cognitiva fundamental en el aprendizaje de las ciencias. Entre los objetivos relacionados con la educación científica se incluye el aprendizaje de la naturaleza y utilización de los modelos establecidos, su papel en el desarrollo del conocimiento científico y el arte de la modelización (11). Todos estos aprendizajes involucran la formación de representaciones conocidas como modelos mentales, las cuales a su vez implican la visualización. En el caso de los modelos mentales, el pensamiento metacognitivo se realiza sobre las entidades que lo componen y sus interrelaciones. En el caso de la modelización, ese

pensamiento es sobre la manera en que las entidades y sus relaciones han sido establecidas (11).

Los estudios de habilidades visuales en estudiantes se han desarrollado para la visualización tridimensional a partir de representaciones bidimensionales en química (12) y en biología (13), la detección de dificultades en la interpretación de cortes y secciones de imágenes (14), y el diagnóstico de competencias para obtener información al cambiar un objeto de posición (13).

En general se ha concluido que, a menos que medie una amplia experiencia en el trabajo conciente con la lectura de imágenes, el mismo resulta problemático y un obstáculo para el aprendizaje (15).

Distintos estudios han comprobado que los

estudiantes tienen dificultad para comprender la representación gráfica de objetos tridimensionales (16). En modo semejante a lo reportado en este trabajo, Allen (17) observó que los estudiantes universitarios carecían de experiencia en el uso y la generación de imágenes. Los puntajes que obtuvo este investigador para la capacidad de visualización presentaron un rango de 53 a 92%.

Levie y Lentz (18) comprobaron que, aun con instrucciones explícitas de leer cuidadosamente un texto ilustrado, más de la mitad de los estudiantes no consideraba las imágenes o sólo lo hacían para divertirse mientras leían. Además, de la misma forma que se observó en este trabajo, los estudiantes sólo apreciaban el aspecto general de las imágenes, ignorando los detalles. Llorente Cámara (15) señala que los estudiantes carecen de hábitos para aprender de las imágenes por considerar que las mismas no son una fuente de información útil. Estas observaciones resultan coincidentes con algunos resultados del presente trabajo en cuanto a que la mayoría de los estudiantes entrevistados consideraron a las tareas realizadas durante la investigación como “dificultosas” o “muy dificultosas” por su falta de costumbre en resolver las tareas solicitadas y considerar a las ilustraciones como elementos de distracción.

Recomendaciones didácticas

Con miras a proponer algunas sugerencias para el desarrollo de actividades que enriquezcan las habilidades de visualización de los estudiantes, resulta adecuado presentar una definición operativa. Lengler y Eppler (19) consideran que un método de visualización “es una representación sistemática, basada en reglas, externa y gráfica que retrata o describe una información de manera tal que conduce a (o favorece) la adquisición de entendimiento, el desarrollo de una comprensión elaborada o la comunicación de experiencias.” En este sentido, cuando los docentes elaboramos representaciones sistemáticas para promover habilidades

de visualización deberíamos tener en cuenta:

a- Clarificar las interrelaciones entre los componentes de un objeto o las etapas de un proceso, más que reproducir con exactitud el mundo natural. Uttal y cols. (20) señalan al respecto que un diseño de instrucción donde se enfaticen las relaciones será más exitoso que otro que se esfuerce en ser realista.

b- Diseñar actividades manteniendo el contexto entre diferentes partes de un objeto o proceso. Por ejemplo, cuando se utiliza una serie de diagramas para describir o explicar un concepto o proceso científico es importante que los estudiantes pongan atención en cómo un detalle o un paso específico en una progresión se relaciona con el contexto en su totalidad.

c- Secuenciar las actividades tratando de reflejar la organización mental que el estudiante estaría desarrollando. De esa forma, si se está creando una serie de imágenes para representar un proceso, el instrumento de aprendizaje debería contener una serie similar con propósitos comparativos. O bien, en el caso de crearse una “película mental”, una animación será más efectiva que otras formas de representación (21). Estos puntos se asocian con la adecuada selección o elaboración de los recursos didácticos. En los mismos pueden incluirse elementos para ejercitar la visualización y que habrán de corresponderse con, al menos, alguna de las tres categorías establecidas por Rieber (22):

a.- Representacional: cuando se recupera al objeto en un rango de representaciones que van desde las formas más realistas (como las fotografías) hasta otras más abstractas (esquemas de líneas).

b.- Analógica: cuando se utilizan representaciones de un objeto con cualidades similares a las del objeto en estudio para destacar características particulares o fenómenos.

c.- Arbitraria: cuando se emplean representaciones gráficas que se asemejan al concepto en cuestión pero revelan información a través de sus características espaciales y las relaciones entre sus diferentes elementos (por ejemplo: mapas, gráficos, mapas conceptuales, tablas).

Como actividades puede trabajarse la visualización de:

- a.- Datos: consistente en el trabajo con formatos cuantitativos estandarizados (tablas y diferentes tipos de gráficos), que deben ser reelaborados como textos.
- b.- Información: la cual emplea redes conceptuales, que deben ser transformados en imágenes. Cabe considerar que las imágenes elaboradas pueden cambiar a medida que avanza el trabajo de análisis.
- c.- Conceptos: centrada en el análisis de mapas conceptuales. En general, se trata de un único concepto cuya definición debe ser elaborada a partir del mapa conceptual, en el cual los conectores deben estar claramente expresados.
- d.- La visualización compuesta: es una combinación de varias de las formas enunciadas anteriormente. Por ejemplo, se acompaña un mapa conceptual con la representación gráfica del concepto.

Además de las actividades señaladas anteriormente, puede recurrirse a estrategias basadas

REFERENCIAS

1. Giorgis C, Johnson NJ, Bonomo A, Colbert C. (1999). Visual literacy. *The Reading Teacher*; 53(2):146-153.
2. Mathewson JH. (1999). Visual-spatial thinking: An aspect of science overlooked by educators. *Science Education*; 83(1): 33-54.
3. Messaris P. (1995). Visual literacy and visual culture. *Image and visual literacy: Selected readings from the Annual Conference of the International Visual Literacy Association*, Octubre 12-16. Tempe, Arizona.
<http://www.adobe.com/uk/education/pdf/adobe_visual_literacy_paper.pdf> [Consulta: 14-4-2007].
4. Gilbert JK, Justi R, Aksela M. (2003). Visualization: A metacognitive competence in the learning of science. Cuarta Conferencia European Science Education Research Association (ESERA).
<<http://www1.phys.uu.nl/esera2003/programme/pdf/225S2.pdf>> [Consulta: 14-4-2007].
5. Raj Chaudhury S. (2003). Multiple representations, scientific visualization and student learning of science. National Association of Geoscience's Teachers.
<http://serc.carleton.edu/files/NAGTWorkshops/visualize04/chaudhury_essay.pdf> [Consulta: 3-6-2007]
6. Mathewson J.H. (2005). The visual core of science: definition and applications to education. *International Journal of Science Education*; 27(5):529-548.
7. Galagovsky L, Adúriz-Bravo A. (2001). Modelos y analogías en la enseñanza de las ciencias naturales. El concepto de modelo didáctico analógico. *Enseñanza de las Ciencias*; 19(2):231-242.
8. Prendes Espinoza MP. (1996). Análisis de imágenes en textos escolares. *Revista Pixel-Bit - Revista de Medios y Educación* 6. <<http://www.sav.us.es/pixelbit/articulos/n6/n6art/art6.htm>> [Consulta: 12-12-2004]
9. Jiménez Valladares JD, Perales Palacios FJ. (2002). La evidencia experimental a través de la imagen de libros de texto de física y química. *Revista Electrónica de Enseñanza de las Ciencias*, 1(2).
<<http://www.saum.uvigo.es/reec/volumenes/volumen1/Numero2/Art5.pdf>> [Consulta: 10-5-2005]
10. Barnea N. (2000). Teaching and learning about chemistry and modelling with a computer managed modelling system. En: *Developing Models in Science Education*, Gilbert JK & Boulter CJ (eds) Kluwer Academic Publisher,

Dordrecht, pp. 307-324.

11. Gilbert JK, Boulter CJ, Elmer R. (2000). Positioning models in science education and in design and technology education. En: *Developing Models in Science Education*, Gilbert JK & Boulter CJ (eds), Kluwer Academic Press, Dordrecht, pp. 3-18.
12. Tuvi-Arad I, Gorsky P. (2007). New visualization tools for learning molecular symmetry: a preliminary evaluation. *Chemistry Education Research and Practice*; 8(1): 61-72.
13. Macnab W, Johnstone AH. (1990). Spatial skills which contribute to competence in the biological sciences. *Journal of Biological Education*; 24(1):37-41.
14. Constable H, Campbell B, Brown R. (1988). Sectional drawings from science textbooks: an experimental investigation into pupils understanding. *British Journal of Educational Psychology*; 58:89-102.
15. Llorente Cámara E. (1999). Imágenes en la enseñanza. *Revista Psicodidáctica* 9. <<http://redalyc.uaemex.mx/redalyc/pdf/175/17500911.pdf>> [Consulta: 9-8-2006]
16. Scribner SA, Anderson MA. (2005). Novice drafters' spatial visualization development: Influence of instructional methods and individual learning styles. *Journal of Industrial Teacher Education*; 42(2):38-60.
17. Allen AD. (1999). Complex spatial skills: the link between visualization and creativity. M.Sc Thesis, Faculty of the Virginia Polytechnic Institute and State University, Blacksburg, Virginia, 97pp.
18. Levie WH, Lentz R. (1982). Effects of text illustrations: A review of research. *Educational Communication and Technology Journal*; 30:195-232. Op. Cit. Llorente Cámara, E. 1999.
19. Lengler R, Eppler MJ. (2007). Towards a periodic table of visualization methods for management. IASTED Proceedings of the Conference on Graphics and Visualization in Engineering (GVE 2007), Clearwater, Florida, EEUU. <http://www.visual-literacy.org/periodic_table/periodic_table.pdf> [Consulta: 11-3-2007]
20. Uttal DH, Liu LL, DeLoache JS. (2006). Concreteness and symbolic development. En: Balter, L & Tamis-LeMonda, C. *Child Psychology*, Cap. 8, 167-185. Disponible en: <https://www.depot.northwestern.edu/projects/wcas/psych/uttallab/WebPublications/uttalliudeloache2006c_hap150.pdf> [Consulta: 11-3-2007]
21. Tversky B, Morrison JB, Betrancourt M. (2002). Animation: Can it facilitate? *International Journal of Human-Computer Studies*; 57:247-262.
22. Rieber L. (2002). Supporting discovery-based learning with simulations. International Workshop on Dynamic Visualizations and Learning. Online-Proceedings, Knowledge Media Research Center (KMRC), Tübingen, Germany. <<http://www.iwm-kmrc.de/workshops/visualization/rieber.pdf>> [Consulta: 21-3-2007]

TESIS DE MAESTRÍA EN ANATOMÍA Y FISIOLOGÍA ANIMAL.

**LECTINHISTOQUÍMICA DEL EPITELIO INTESTINAL
EN LOS MAMÍFEROS DOMÉSTICOS.
ESTUDIO COMPARATIVO ENTRE EL EQUINO, EL CERDO Y EL CONEJO.**

Autor: Méd. Vet. Jorge M. GALOTTA
Director: Dr. Claudio BARBEITO
Lugar: Universidad Nacional de Río Cuarto
Fecha: junio de 2006

Resumen

Las lectinas son proteínas y glicoproteínas de unión específica a residuos de azúcares dentro de oligosacáridos y polisacáridos. La lectinohistoquímica es una técnica que utiliza a estas proteínas para determinar el patrón de sacáridos en los tejidos. En la presente tesis se realizó un estudio lectinohistoquímico de diversas regiones del intestino del cerdo, el equino y el conejo.

A continuación se enumeran las lectinas que se utilizaron para incubar los cortes, agrupadas según su afinidad por los distintos carbohidratos:

Grupo I: afinidad por glucosa / manosa

Con A (*Concanavalina ensiformes*)

Grupo II: afinidad por Nacetilglucosamina

WGA (*Triticum vulgare*). Esta lectina también posee afinidad por el ácido siálico

Grupo III: afinidad por Nacetilgalactosamina / galactosa

DBA (*Dolichus biflorus*)

SBA (*Glycine max*)

PNA (*Arachis hypogaea*)

RCA I (*Ricinus communis*)

Grupo IV: afinidad por L fucosa

UEA I (*Ulex europeus*)

Se utilizaron el complejo biotina-avidina (ABC) para la amplificación, la diaminobencidina (DAB) como cromógeno y la hematoxilina para la coloración de contraste. Los cortes se evaluaron por microscopía óptica. Se analizaron los enterocitos (EC) y células caliciformes (CC) de criptas y vellosidades, se consideraron variaciones zonales entre la región basal y superficial de estas estructuras. De acuerdo a La unión de las lectinas fue evaluada subjetivamente en: (-) negativa, (+) débilmente positiva, (++) positiva y (+++) fuertemente positiva.

La marcación con la lectina CON A resultó negativa para las células caliciformes, con excepción de algunas células del recto del cerdo y equino. El comportamiento de la marcación de los EC con CON A no indicó un patrón que pudiera relacionarse con el eje cráneo-caudal del intestino. Así, mientras en el conejo la marcación se hizo más intensa hacia el intestino grueso, en el cerdo, la lectina CON A mostró una mayor afinidad en el intestino delgado, en especial en el íleon. En el equino la menor afinidad se encontró en el colon.

Con respecto a la lectina WGA, el patrón de marcación en las CC fue heterogéneo, tanto para las distintas especies, como para los distintos sectores intestinales estudiados. En el conejo, la intensidad de la marcación fue escasa y llegó a ser negativa en íleon. En el equino la marcación también fue leve, excepto en el íleon donde resultó intensa. Los E se marcaron con WGA en todos los sectores estudiados.

La lectina DBA marcó en forma heterogénea las CC de los distintos sectores intestinales, con excepción del colon del cerdo en el que no se encontró marcación. En algunos casos, como en el intestino grueso del conejo, las células positivas predominaron en el fondo de la cripta. Sin embargo en el intestino grueso del equino y en el yeyuno del conejo las células marcadas predominaron en la región más cercana a la luz. Con respecto a los EC del intestino delgado y del colon del cerdo, no se evidenciaron en ellos sitios de unión para DBA. En cambio, en el recto se observó marcación en las células superficiales. En el recto del equino se encontró un resultado positivo como en el cerdo, pero también se halló marcación en otros sectores del intestino como el yeyuno y la base de las criptas del íleon y colon. En el conejo, no se evidenciaron sitios de unión para DBA en el intestino grueso. Con respecto al intestino delgado de esta especie, el patrón de marcación es fue poco habitual, ya que en el íleon la positividad fue mayor en el fondo de las criptas intestinales mientras que en el yeyuno lo fue en la superficie.

La lectina SBA marcó las células caliciformes, excepto en el colon de caballo y cerdo. En los EC la lectina SBA marcó tanto el glicocáliz como el citoplasma en la mayor parte de los casos. Además, con esta lectina, fue frecuente el hallazgo de un patrón de marcación supranuclear. Este último patrón puede relacionarse, por su ubicación intracelular, con la marcación del aparato de Golgi.

La marcación con PNA en CC fue negativa en el intestino delgado, excepto en algunas células del equino. Los EC se evidenciaron con PNA. Esta marcación fue más frecuente en las células de las vellosidades que en las de las criptas.

RCA-I marcó en forma heterogénea las CC, con excepción del intestino grueso del equino en que no hubo marcación alguna. En los EC del conejo y del equino la marcación fue más intensa en el intestino delgado, mientras que en el cerdo la menor marcación se observó en el yeyuno. En general, en el cerdo se encontró una elevada positividad para RCA-I, lo que se corresponde con lo observado por otros investigadores.

PNA, SBA, DBA y RCA-I forman un grupo de lectinas con afinidad por galactosa y N-acetilgalactosamina. Sin embargo, la intensidad de la unión puede variar notablemente para ambos monosacáridos. Estas características explican los resultados divergentes encontrados en la misma especie animal y dentro del mismo sector del intestino, para las diversas lectinas del grupo. En la

marcación con estas lectinas encontramos diferencias regionales en las criptas del intestino grueso, variando la intensidad de la misma según la hilera celular considerada.

La lectina UEA-I, que determina la presencia de fucosa, marcó intensamente en la mayoría de las CC excepto en el intestino delgado del conejo, en el colon del caballo y el recto del cerdo.

Nuestros resultados permiten establecer un patrón general de unión a lectinas en el intestino de distintas especies de mamíferos domésticos. Este patrón debe considerarse característico dentro de ciertas condiciones ya que puede variar en situaciones fisiológicas como la edad o con distintas dietas. También debe considerarse que las diferencias intra e interespecíficas en el patrón de glicosilación de la mucosa intestinal estarían relacionadas con la fisiología de ese sector del intestino y con la interacción entre el epitelio y los microorganismos intestinales y por lo tanto son, al menos parcialmente, el resultado de un proceso coevolutivo. Aun más, estas variaciones no solo son producidas por el efecto directo de los microorganismos sino también por la acción que las citoquinas secretadas por el hospedador ejercen sobre las células intestinales.

Otro aspecto relevante de nuestros resultados es la diferencia entre el patrón de carbohidratos entre los EC y CC. Esto coincide con lo observado en otras especies y se relaciona con el hecho que, si bien ambas células sintetizan mucinas, el control de la secreción es diferente en estas dos poblaciones celulares.

En síntesis, nuestro estudio revela la existencia de variaciones en el patrón de carbohidratos en distintas especies, sectores intestinales, regiones del eje cripta-vellosidad y tipo celular. No se evidenció una relación directa con el tipo de dieta ya que no se estableció un patrón común para las tres especies, lo que podría explicarse por la multicausalidad en la variación de la composición de los glicocomplejos intestinales. La importancia de nuestro estudio reside en que analiza tanto distintas especies como diferentes sectores intestinales, mientras que la mayoría de los trabajos consultados se limitan a la descripción del patrón de lectinohistoquímica en una única especie y en algunos segmentos intestinales.

Abstract

Lectins are proteins that bind specifically to terminal carbohydrate residues in oligosaccharides and polysaccharides. Lectin histochemistry is a technique that employs these proteins to determine the pattern of saccharides in tissues. In the present thesis a lectin histochemical study of diverse regions of the intestine of horses, pigs and rabbits was performed.

The lectins employed to incubate the histological sections, grouped according to their affinity to different carbohydrates, are indicated next:

Group I: affinity for glucose / mannose

Con-A (*Concanavalia ensiformes*, specifically binding -D-Man and -D-Glc)

Group II: affinity for Nacetylglucosamine

WGA (*Triticum vulgare*, binding specificity -D GlcNAc and NeuNAc). This lectin has also affinity for sialic acid.

Group III: affinity for N acetyl galactosamine / galactose

DBA (*Dolichus biflorus*, with binding specificity to -D-GalNAc)

SBA (*Glycine Maxima*, binding specificity to -D-GalNAc, -D-galNAc and -Gal)

PNA (*Arachis hypogea*, that specifically binds -D-Gal and (1-3) GalNAc)

RCA-1 (*Ricinus communis*-1, binding specificity -D-Gal and -D-Gal)

Group IV: affinity for L fucose

UEA-1 (*Ulex europaeus*-1, binding specificity LFuc)

The jejunum, ileum, colon and rectum slides were incubated with an avidin-biotin-peroxidase complex for amplification. Diaminobenzidine and hematoxylin were used as chromogen and contrast staining, respectively. Enterocytes (EC), goblet cells (GC) from villi and crypts were analyzed and zonal variations between basal and surface regions of these structures were taken in consideration. The intensity of lectin binding was subjectively scored as follows: (-) none, (+) weakly positive, (++) positive, (+++) strongly positive.

CON A labelling resulted negative for goblet cells except for scarce cells in the pig's and horses' rectum. The enterocytes CON A labelling did not show a pattern that could be related to the cranial-caudal intestine axis. Thus, in the rabbit the labelling resulted more intense toward the large bowel whereas in the pig it revealed a greater affinity in the small bowel, particularly in the ileum. In the horse, CON A minor affinity was found in the colon.

Regarding WGA, there was a heterogeneous GC lectin binding pattern both, among species and different intestinal sectors. In the rabbit, the intensity of the bearing was little and got to be negative in ileum. In horses the labelling also was weak, except in ileum where it was intense. Enterocytes were positive for WGA in all the studied sectors.

Lectin DBA produced heterogeneous staining of the GC in the different intestinal sectors, with exception of the pig's colon which was not labelled. In some cases, as in the large intestine of the

rabbit, the positive cells predominated at bottom of crypt. Nevertheless in the horse's large intestine and rabbit's in jejunum the labelled cells predominated in the superficial cells. With respect to the EC of the small intestine and the colon of the pig, no DBA binding sites were demonstrated. However, labelling of the superficial cells was observed in the rectum. In the horse there was a positive result as in the pig, but staining was also found in other sectors of the intestine, i.e. jejunum and the crypt's base of ileum and colon. In the rabbit, no DBA binding sites were demonstrated in the large intestine. With respect to the small intestine of this species, the labelling pattern was unusual, since in the ileum the positive staining was greater at the bottom of the crypts whereas in jejunum it was revealed in the surface.

Lectin SBA labelled GC, except in the colon of horse and pig. In the E this lectin labelled glycocalyx and the cytoplasm in most of the cases. In addition, the finding of a pattern of supranuclear staining with this lectin was frequent. This last pattern can be related, by its intracellular location, with the labelling of the apparatus of Golgi.

PNA staining in GC was negative in the small intestine, with the exception of some cells of the horse. The EC were demonstrated with PNA; this labelling was more frequent in the villi than in those of crypts.

RCA-I bound in a heterogeneous form to GC, with exception of the large bowel of the horse in which there was no labelling. In the EC of the rabbit and the horse the staining was more intense in the small bowel, whereas in the pig the minor staining was observed in jejunum. In general, in the pig a high RCA-I labelling was found, in good agreement to observations from other investigators.

PNA, SBA, DBA and RCA-I constitute a group of lectins that display high affinity for galactose and *N*-acetylgalactosamine. However the binding intensity can vary notably for each monosaccharide. These characteristics explain the divergent results found for the diverse lectins of this group, in a single animal species within a same intestinal sector. We found regional differences in the labelling of these lectins for the large bowel crypts as the intensity of staining varied according to the cell tier.

The UEA-I lectin, that determinates fucose presence, labelled strongly most of the GC with the exception of the small intestine of the rabbit, the colon of horse and the rectum of the pig.

Our results allow us to establish a general lectin binding pattern in the intestine of different domestic mammalian species. This pattern should be considered within certain conditions for it may be modified according to different physiological conditions such as age or diet. Also, regional and interspecific differences of the mucin could reflect the interaction between epithelium-microorganisms and the effects of various cytokines produced by the host in response to such interaction. These interactions could modify the glycolisation pattern, as a result of a coevolutive process.

Another relevant aspect of our results is the differential carbohydrates pattern found in GC and EC. This is in coincidence with reports for other species and can be related to the fact that, although both cellular types produce mucin, the regulatory secretion control is different in each cell-type.

In synthesis, our study reveals the existence of variations in the carbohydrate pattern in different species, intestinal sectors, regions along the crypt-villus axis and cellular type. A direct relation to the type of diet was not demonstrated since a common pattern for the three species was not settled down; this could be explained by the multicausality in the variation of the composition of the intestinal glycoconplexes. The importance of our study resides in that it analyzes different species as much as different intestinal sectors, whereas most of the consulted investigations are limited to the description of the lectin histochemical pattern in a single species and in some intestinal segments.

Sociedad de Ciencias Morfológicas de La Plata
(La Plata Morphological Sciences Society)

Resúmenes del **IX CONGRESO y 6^{tas} JORNADAS DE EDUCACIÓN**
Abstracts from the IX Congress and 6th Education Workshop

30 Y 31 DE AGOSTO DE 2007
CENTRO CULTURAL ISLAS MALVINAS
LA PLATA; ARGENTINA

Edición: Magíster Norma González
Edited by Norma González Msc

(1)
**STUDY OF THE EXPRESSION OF VASCULAR ENDOTHELIAL GROWTH
FACTOR AND THE ADN SYNTHESIS OF MOUSE DURING LIVER
REGENERATION**

Andrini LB; García MN; Inda AM; Errecalde AL.

Cátedra de Citología, Histología y Embriología "A". Facultad de Ciencias Médicas, Universidad Nacional de La Plata. La Plata, Argentina.

E-mail: landrini@med.unlp.edu.ar

Angiogenesis is stimulated by the vascular endothelial growth factor (VEGF). The aim of this study was to compare the expression of VEGF and the DNA synthesis (DNAs) throughout a circadian period in the liver of hepatectomized mice. Adult male C3HS mice under standard conditions for periodicity analysis were used. The animals were hepatectomized at 10:00 h and killed at 12/26, 16/30, 20/34, 00/38, 04/42, 08/46 and 12/50 (hour of day/hour poshepatectomy). They were divided in 2 groups in order to study: A- the expression of VEGF and, B- the index of DNAs. The mice of group B were injected intraperitoneally with 5- BrdUrd at a dose of 50 mg/kg of body weight, one hour before they were killed. Liver samples were processed for immunohistochemistry for the detection of VEGF and DNAs. In each sample we registered the number of positive cells over a total of 3000 cells. The results were analysed with the Student *t*-test. In the curves of both groups we found significant differences ($p < 0.01$) at 16/30, 20/34 and 12/50. The maximum peak of DNAs was produced between 30 and 34 h poshepatectomy, whereas the peak of VEGF expression was produced 46 h poshepatectomy. We could conclude that the hepatocytes' DNAs was previous to the VEGF secretion. This finding is relevant for this growth factor stimulated the proliferation of the sinusoidal endothelial cells for the formation of blood vessels for the new cells.

(2)

**ADDENDA TO THE TYPES LIST OF ENCYRTIDAE, EULOPHIDAE, AND
EUPELMIDAE (HYMENOPTERA: CHALCIDIDAE) HOUSED AT THE MUSEO DE
LA PLATA, ARGENTINA**

Margaría CB; Aquino DA.

División Entomología, Museo de La Plata. Universidad Nacional de La Plata. La Plata, Argentina.

E-mail: daquino@fcnym.unlp.edu.ar

Insect collections have much to contribute to the understanding of the world's biodiversity. Entomological collection of Museo de La Plata (Argentina) houses almost two millions of specimens, most of which are from Argentina, and 6.000 of them are types. These materials bring an especial national and international relevance, being necessary for species designation. The objective of this contribution is to study the type material of three families of Chalcidoidea to make an inventory and quantify biodiversity. The 29 type specimens of Encyrtidae (18), Eulophidae (10), and Euplemidae (1) (Hymenoptera: Chalcidoidea) housed in the collection of División Entomología, Museo de La Plata, were examined and listed, providing updated information about them. The types belong to 9 species of Chalcidoidea described by Blanchard (1), Boucek (2), De Santis (4), and Noyes (2). Taxa inventory and its inclusion at División Entomología database allows to accede to the systematic information, geographical distribution, hosts and other aspects of biology of these parasitoids that are used in biological control.

(3)

**PATHOLOGICAL HISTOLOGICAL CHARACTERIZATION OF MUCOCELE:
A FREQUENT SALIVARY GLAND PATHOLOGY**

Arcuri M; Bruno M; Mercado M; Micinquevich S; Rom M; Salvatore M; Del Viso S.

Asignatura Patología y Clínica Estomatológica. Facultad de Odontología de La Plata, Universidad Nacional de La Plata. La Plata, Argentina.

E-mail: monicagrom@yahoo.com.ar

The mucocele is a cystic or pseudo-cystic lesion of the minor salivary glands which may be clinically superficial or deep without predilection for age or sex. A mucoceles series, collected throughout a five years period, in the Pathology and Clinical Stomatologic Laboratory at La Plata Faculty of Odontology were analyzed. Variables as age, sex, location, shape and color were taken into account. The patients' average age was 24.85, ranging from 8 to 79 years. The lesions were found in 43.4% of the women and 56.5% of the men. The most frequent location was the lower lip (84.05%). The ovoid shape and blue translucent color were the aspects more frequently found. By using an optical microscope, it was observed two kinds of images: 1) mucooid material in a fibrous cavity with granulation tissue and inflammatory infiltrate; 2) a mucooid cavity covered by stratified squamous epithelium and granulation tissue with the typical infiltration of mononuclear lymphocytes and plasmocytes. According to these findings, we concluded that the most frequent location was the lower lip. The majority of the cases occurred in the third decade of life. In correspondence to other author's results, the histological parameters corresponded to the pseudo-cystic variants by extravasations and only one of the cases belonged to the cyst by retention.

(4)

**DETERMINATION OF QUANTITY AND QUALITY OF SALIVA
AS CARIES RISK FACTOR**

Armendano A; Crimaldi D; Mendes C; Mastrancioli M; Rasse N; Obiols C; Durso G.
Facultad de Odontología. Universidad Nacional de La Plata. La Plata, Argentina.
E-mail: leo_aku9000@hotmail.com

Saliva has, among many, a very important function related to caries activity: 1) buffer capacity that relates mouth pH and to the degree of acidity or alkalinity; 2) sugars dilution, related to salivary flow; 3) remineralization capacity, and 4) formation of acquired salivary pellicle. The aim of this work was to relate saliva quantity and quality to caries incidence and to the degree of pathogenicity of *Streptococcus mutans* and *Lactobacillus sp.* in a population of children aged 6-12 years old who were assisted by the Children Integral Odontology Chair at the La Plata School of Dentistry. Medical histories were made with the pertaining odontogram. The O'Leary index was used as well as the qualitative register following the Snyder method to determine the saliva quality (acid or alkaline) according to the speed in the shift from green to yellow color. The quantitative method employed was the recounting of *S. mutans* and *Lactobacillus* colonies, considering the number of colonies with the following register: 0-500 null; 500-1000 slight; 1000-5000 moderate; 5000-10.000 susceptible and over 10.000 very susceptible. Results, detected by O'Leary index, indicated 28% patients without caries risk and 72% with risk activity. Qualitative register: 70% susceptible patients, 19% moderate, 7% slight and 4% null. *Streptococcus* quantitative register were 56%; 20%; 17% and 7% for very susceptible; susceptible, moderate and slight susceptible patients whereas the *Lactobacillus* register showed: 7% very susceptible, 73% susceptible and 20% moderate susceptible patients. We concluded that the quantity and quality of saliva are determining biological caries risk factors.

(5)

**SENSITIVE STRUCTURES OF *Cephalobium* sp, A PARASITE OF CRICKETS:
COMMENTS TO SEM**

Camino NB; Achinelly MF; Schargorodsky G.

Centro de Estudios Parasitológicos y de Vectores, CEPAVE, Universidad Nacional de La Plata. La Plata, Argentina.

E-mail: nemainst@cepave.edu.ar

The study of sensitive structures in nematodes is an important tool for species identification. The survey of insect pests in crops of Greater La Plata, showed the presence of a population identified as *Anurogryllus muticus* De Geer, parasitized by nematodes of the genus *Cephalobium* sp. Ultrastructural studies at cephalic level were conducted to characterize this species. Insects found in the area were collected manually and then placed in plastic containers tightly closed. In the lab insects were conditioned for the discovery of nematodes. Parasites were killed in distilled water at 60° C for 2 minutes and set in TAF (triethanolamine, formaldehyde and distilled water). To study the morphology of the sensitive structures, the specimens were prepared for electron microscope observation. The nematodes were dehydrated in an increasing alcohol series and then coated in gold 24 in argon plasma. Observations of ultrastructure were performed using a scanning electron microscope (SEM) JEOL JSM-100). The results showed the structure of the anterior end of *Cephalobium* sp, with six labial finger-shaped papillae situated on a first ring around the mouth. The second ring was larger than the previous one, with six globular papillae and an fids head, body chemoreceptors, with an oval pore edge well marked, opening laterally. Mouth was triangular and terminally localized. The remaining rings were equal in size and shape. In regard to these results, we can conclude that these characters associated with male and female genitals led us to identify this species as new to science.

(6)

ADDITION OF DYS438 IN Y-CHROMOSOME HAPLOTYPES OF AMERINDIANS

Catanesi C¹; Silbestro M¹; Méndez MG²; VidalRioja L¹.

1 Instituto Multidisciplinario de Biología Celular (IMBICE). La Plata, Argentina.

2 Departamento de Antropología, Facultad de Ciencias Naturales y Muse. Universidad Nacional de La Plata. La Plata, Argentina.

* CONICET.

E-mail: ccatanesi@imbice.org.ar

The study of Y-chromosome variation is useful to clarify the origin and geographic precedence of humans. The Y-chromosome is paternally inherited, and a man transmits his Y-specific genetic polymorphisms to all his male descendants, conforming a male lineage. Among the different kinds of Y-chromosome polymorphisms, the microsatellite or STR (short tandem repeat) loci are very informative due to their high allelic variability; DYS438 is a STR of pentanucleotide repeated sequence. We analyzed DNA from 96 Amerindian males, 83 of them belonging to the Gran Chaco ethnic groups Mocoví (n=27), Chorote (n=12), Wichí (n=14), Toba (n=4), Lengua (n=17), and Ayoreo (n=9), and 13 to the Patagonian Tehuelche. DYS438 was analyzed through PCR and 6% denaturing polyacrylamide gel electrophoresis. Gels were stained with AgNO₃ for visualization of bands. We found alleles 10, 11, 12 and 13, but only two or three of them in every ethnic group, being allele 11 the most frequent for all of the tribes, and allele 13 only found among Tehuelche. Several individuals have been previously analyzed for other Y-STRs which are inherited altogether, composing Y-haplotypes. The inclusion of this marker, allowed differentiating Tehuelche individuals who previously shared identical haplotypes. However, for the Chaco samples, this marker did not increase haplotype diversity. We conclude, the variability of DYS438 is lower than that of other Y-markers (eg. DYS385 and DYS392) in Amerindians. The analysis of a higher number of samples will allow confirming these results in the future.

(7)

**COEXISTENCE OF UNDERNUTRITION AND EXCESS OF WEIGHT IN
PRESCHOOLER CHILDREN RESIDENTS IN URBAN, PERIURBAN, AND RURAL
AREAS**

Cesani MF^{1,2}; Zonta ML^{2,4}; Castro L³; Torres MF^{4,5}; Forte LM⁶; Orden AB^{1,2}; Quintero FA^{1,3}; Luis MA³; Sicre ML³; Luna ME¹; Oyhenart EE^{1,2,3}.

1 Centro de Investigaciones en Genética Básica y Aplicada (CIGEBA,, Facultad de Ciencias Veterinarias. Universidad Nacional de La Plata. La Plata, Argentina.

2 Consejo Nacional de Investigaciones Científicas y Técnicas (CONICET).

3 Facultad de Ciencias Naturales y Museo, Universidad Nacional de La Plata. La Plata, Argentina.

4 Centro de Estudios Parasitológicos y de Vectores (CEPAVE), Universidad Nacional de La Plata.

5 Sección Antropología Biológica, Facultad de Filosofía y Letras, Universidad de Buenos Aires. Ciudad Autónoma de Buenos Aires, Argentina.

6 Instituto de Geomorfología y Suelos. Facultad de Ciencias Naturales y Museo, Universidad Nacional de La Plata. La Plata, Argentina.

E- mail: mfcسانی@fcnym.unlp.edu.ar

The urbanization process in Argentina during the last decades has promoted a development of periurban neighborhoods, characterized by unsafe housing, critical overcrowding, and lack of public services. As a result, poverty among "urban poor" is sometimes similar or greater than that of the rural ones. The objective of this study was to analyze nutritional status in preschooler children living in urban (U), periurban (PU) and rural (R) areas from the Brandsen district (Buenos Aires province). Height and weight were measured in 600 boys and girls. Undernutrition prevalence was estimated based on data from National Center of Health Statistics. Weight/age (W/A), height/age (H/A), and weight/height (W/H) below 5th percentile, were considered as indicators of low height-for-age, low weight-for-age and low weight-for-height. Overweight and obesity were calculated following the criteria proposed by the International Obesity Task Force. Undernutrition prevalence was similar among U, PU and R (9.0, 9.7, and 10.2%, respectively). The highest indicator was low W/A (PU=9.3%, R=8.0%, U=6.8%). There were significant differences only between urban and periurban children. Low W/H and W/A were below 4.0 and 2.6%, respectively. The excess of weight was high in the three areas. Overweight was significantly higher in R (22.9%) compared with U (12.0%) and doubled obesity, which was similar among areas (U: 6.0%, PU: 6.9%, R: 11.0%). These results suggested that PU presented the worst socio-environmental conditions for preschooler children's growth and health. Undernutrition and excess of weight coexistence could be associated with changes in nutritional patterns and life styles of these populations.

(8)

COMMON LOCALIZATIONS OF FACIAL BUTTRESSES

Coscarelli L; Arcamone L; Buezas M; Cerezo M; Perez Fre D.

Cátedra de Anatomía "A", Facultad de Ciencias Médicas. Universidad Nacional de La Plata. La Plata, Argentina.

E-mail: leonardocoscarelli@hotmail.com

As fractures of the facial bones are of common occurrence, we state that there are areas where bone is weaker or stronger to impact. From the study of the craniofacial architecture emerges the presence of resistance or protection areas that conducts impact forces to weaker areas where fractures take place. These areas include laminar bone sectors forming the maxillary and frontal sinuses, as well as the emergence of nerve bundles. Resistant areas correspond to compact bone, as true protecting columns called craniofacial buttresses. The term buttress corresponds to a gothic structure used as arches over a vault to distribute forces. Facial skull has a series of compact bone buttresses that forms a protecting framework for the craniofacial cavities (orbits, nasal fossae, oral cavity and paranasal sinus), which walls are mostly thin and fragile. Such buttresses distribute forces through the facial bones and have a strategical disposition in each of the three thirds: superior, half and inferior. Present work was based on a bibliographical review as well as the study of 15 skulls submitted to facial traumatism, performed via falling from high and direct impact. Thus, as a conclusion, the presence of facial bones' resistance areas in the ascending ramus of the maxillary bone, nasal bones, orbit internal edge, and body of maxilla articulated with palatine and pterigoid bones, and body of maxilla with external orbit edge and malar and mandibular bodies, would be in correspondence with the following buttresses: 1-maxilonasalorbital, 2-maxilopterigoid, 3-maxilogomaticmalar and 4-mandibular buttresses.

(9)

**EVALUATION OF THE OUTCOMES FROM THE USE OF LEARNING
STRATEGIES IN HUMAN ANATOMY**

Coscarelli L; Arcamone L; Buezas M; Cerezo M; Perez Fre D.

Cátedra de Anatomía "A", Facultad de Ciencias Médicas. Universidad Nacional de la Plata. La Plata, Argentina.

E-mail: leonardocoscarelli@hotmail.com

Main cognitive mechanisms for information processing are: acquisition, codification and recovery. Thus, learning cognitive strategies can be defined as efficient sequential mental processes used to acquire, retain, recover and use different types of information or to improve cognitive functions. The purpose of this study was to evaluate the improvement of learning abilities in students using study strategies in comparison to those who do not use them. For this purpose ACRA, a method to measure the use of techniques of acquisition, codification and recovering of information was implemented in 54 students from a course of Human Anatomy. In particular, the way students used methods for codification of information was analyzed, correlating data with secondary school average marks and anatomy final exam mark. It can be concluded that those students that had better performance in secondary school used more codification strategies, and those that used more learning strategies, had better results in Anatomy learning.

(10)

**USE OF NEW TEACHING TECHNOLOGIES: WEB-BASED FORUM
OF HUMAN ANATOMY**

Coscarelli L; Arcamone, L; Buezas M; Cerezo M.

Cátedra de Anatomía "A", Facultad de Ciencias Médicas. Universidad Nacional de La Plata. La Plata, Argentina.

E-mail: leonardocoscarelli@hotmail.com

The present work explains the use of new technologies in teaching human anatomy. A web-based forum was created, and students and teachers were invited to join it as part of a virtual community to share ideas, sensations, learning materials, scopes of anatomy subject and all other aspects concerning the development of a medicine student. Forum has different areas, where members can access for free after filling in personal data, incorporation of a picture and a brief explanation of their interests in joining the forum. This virtual space has a messaging area, where students can post doubts, experiences, etc. related to anatomy learning, as well as a download area to share files created using Word and Acrobat reader platforms. Thus, the forum intends to generate a humanistic and scientific formation of students. The third and fourth options that the forum offers are photo-albums and the possibility of making surveys referred to subjects to election to know what and how the members think, respectively. We conclude that the articulated use of a virtual classroom for e-learning encourages the relationship between students and teachers, reinforcing communication from both sides.

(11)
BIOLOGY OF DENTAL CARIES

Crimaldi D; Rasse N; Medina JL; Pilone L.

Facultad de Odontología, Universidad Nacional de La Plata. La Plata, Argentina.

E-mail: rassenicolas@hotmail.com

Dental caries is a multifactorial disease prevalent in the mouth; with those multiple factors forming the bacterial plaque. The two most important are sucrose-dependent and pits and grooves (Miller). The two matrixes sustain and serve as the basis for storable carbohydrates and anaerobic and acidogenic microorganisms. As an aggression microorganisms release enzymes that act on storable carbohydrates and these are degraded in to lactic acid, low pH (3.8) and produce the inorganic substance decalcification and organic proteolysis. The objective of this work was to assess the biologic incidence of caries in first-year students who attend at the La Plata School of Dentistry. Relevant substances, clinical elements (gripper, mirror and explorer) and gloves were used to constitute a randomly-taken sample. Data were processed in pre-designed cards. The results showed that, on a 910 dental pieces examined: a) 107 teeth were affected by caries; b) 52 teeth were missing, and 3) 178 dental pieces were sealed. In the sample under study, dental caries resulted in a prevalent disease of purely biological origin which we need to prevent with plans featuring motivation, execution and evaluation.

(12)

**ASYMMETRY IN SPECIMENS OF *Odontesthes bonariensis*
IN ARTIFICIAL ENVIRONMENTS**

Cuello M¹; García M¹; Solari A¹; Somoza G².

¹ División Zoología Vertebrados, Museo de La Plata. La Plata, Argentina.

² Instituto de Investigaciones Biotecnológicas-Instituto Tecnológico de Chascomús (IIB-INTECH). Chascomús, Argentina.

E-mail: mariela_cuello@hotmail.com

In the first decades of the 20th century, the fish culture of a local species, the pejerrey bonaerense (*Odontesthes bonariensis*) was initiated in Argentina. This activity transcended to other countries and in 1966, embryos from the Chascomús lagoon were introduced in Japan, where the development of this specie's pisciculture was successfully achieved. Four decades later, fecundate eggs from descendents of the first *O. bonariensis* specimens bred in the Kanagawa Prefecture Experimental Station (Japan) were imported by the IIB-INTECH, Chascomús, Argentine, for the raising and sowing of the Pampasian lagoons. The objective of this work was to analyze the morphological variations of the IIB-INTECH specimens. Individuals under study came from natural-spawning eggs, which were transferred to reservoirs of 3,000 and subsequently 20,000 litres with 1.5% salinity, temperatures from 18 to 20° C, natural photoperiod and fed with *Artemia* nauplii and artificial food for pejerrey. More than thirty specimens, from 71 to 430 mm of standard length were analyzed. Thirty-seven morphometric and 11 meristic characters were measured. Principal Component Analysis (PCA) and MANOVA were chosen to test differences between groups in all the size range analyzed. We observed malformations in gill rakers in all specimens, while the largest individuals examined showed cranial asymmetry, exophthalmia and modifications in the head anterior region. These changes are produced as an answer to environmental conditions and have been described in other fish cultured-species, like salmons (*Salmo salar*), trouts (*Onkorynchus mykiss*), carps (*Cyprinus carpio*) and some Perciformes (*Dicentrarchus labrax* and *Lates calcarifer*).

(13)

**CUTICULAR ALTERATIONS OF GORDIUS AUSTRINUS (NEMATOMORPHA)
PRODUCED BY THE PREDACION OF *Salmo trutta***

De Villalobos C¹; Zanca F².

1 CIC.

2 CONICET.

Facultad de Ciencias Naturales y Museo. Universidad Nacional de La Plata. La Plata, Argentina.

E-mail: villalo@fcnym.unlp.edu.ar

During the summer of 2006, 83 specimens of brown trout (*Salmo trutta*) were collected in different southern lakes of Chile. In the stomach of two females and one male collected in the lake Risopatron a total of four specimens of *Gordius austrinus* were found. For examination by SEM, 5mm fragments of all the worms under study were taken from the middle and posterior end of the body. These fragments were washed with distilled water, dehydrated in an increasing ethanol series, critical point-dried, mounted on bronze blocks and gold-sputter coated. Observations were performed using a JEOL SLM 1000 scanning electron microscope. The investigation of these gordiids showed that the cuticle, of the middle and posterior end of the body, had the epicuticle partly destroyed being observed the layers alternated of the fibres of the endocuticle. In this work is analyzed, for the first time the effects of the predation of *S. trutta* on *G. austrinus*. The strategies to avoid predation that the nematomorphs develop in the freshwater environments where inhabit are discussed.

(14)

**MANDIBLE MUSCLE RECONSTRUCTION IN PHORUSRHACID BIRDS (AVES,
GRUIFORMES, CARIAMAE)**Degrange FJ^{1,2}.¹ División Paleontología de Vertebrados, Museo de La Plata, Universidad Nacional de La Plata, La Plata, Argentina.² CONICET.E-mail: fjdino@gmail.com

To test the traditional hypothesis about carnivorous habits of phorusrhacids, a complete reconstruction has been made of four mandible muscles in *Andalgalornis ferox* Patterson and Kraglievich 1960, comparing muscles attachment points with extant birds (Tinamiformes, Procellariiformes, Falconiformes, Strigiformes, Ciconiiformes). The adductors muscles reconstructed are *m. adductor mandibulae externus*, *m. pseudotemporalis profundus* and the *m. adductor mandibulae ossis quadrati*. The first one has its origin on the fossa temporalis (the shape of the fossa is similar to that of the Procellariiformes). The insertion is located on a lateral area relatively wide, developed above the mandible fenestra. Both scars indicate the presence of a large and powerful muscle to the mandible closure. The *m. pseudotemporalis profundus* and the *m. adductor mandibulae ossis quadrati* have their origin in the *processus orbitalis* of the quadrate and the insertion lies in the posterior region of the mandible, but the first have a more cranial position. Only one abductor muscle (*m. depressor mandibulae*) could be restored in the fossil. Its origin lies in the fossa subtemporalis, which is very similar to that of Procellariidae, although in *Andalgalornis* is in an upper position. Its insertion is placed in the fossa caudalis of the mandible. It seems to be a short and robust muscle that allows a quick open of the jaws. The results obtained here do not imply necessarily that these birds were capable to eat one alimentary item in particular; future studies of muscle recruitment and function are needed to explore this issue more broadly.

(15)

PRENATAL DEATH IN CADMIUM INTOXICATED RATS

Díaz MC¹, Gómez S¹, Najle R¹, Barbeito CG^{2,3}.

¹ Departamento de Ciencias Biológicas. Facultad de Ciencias Veterinarias, Universidad Nacional del Centro del Provincia de Buenos Aires. Tandil, Argentina.

² Departamento de Ciencias Básicas e Instituto de Patología. Facultad de Ciencias Veterinarias. Universidad Nacional de la Plata.

³ CONICET.

E-mail: maridel@vet.unicen.edu.ar

Cadmium (Cd) is a heavy metal highly toxic to man and animals, therefore, it becomes of great significance in environmental toxicology. Despite the numerous bibliographic references on Cd intoxication, few works analyze the effects of a single high dose of Cd. Currently; we are studying the alterations determined by a single Cd subcutaneous dose of 10 mg/kg (as CdCl₂) in pregnant rats. We report the morphology of embryonic resorptions and dead fetuses, observed in the uterus of intoxicated animals. Groups of 6 rats each were treated at different times of pregnancy (4, 7, 10 and 15 days). All animals were sacrificed on day 20 of gestation. Control groups were used for each sampling time. Samples from uterus were processed with conventional histological techniques and stained with H&E. In intoxicated animals' uterus, either embryonic resorptions, indicating early loss of the *conceptus*, as well as abnormal fetuses were found. These findings were not observed in control groups. Resorptions were necrotic masses wherein no embryonic structures could be recognized, but some trophoblastic cells. In abnormal fetuses, size as well as morphological alterations could be macroscopically observed. Microscopically, some well differentiated tissues but without normal distribution and size were observed. In some fetal regions, the presence of inflammatory cells infiltrating the tissues was observed. Changes took place in animals from uterus of females intoxicated to different days of gestation. Described changes were found in embryos from females Cd-intoxicated in different stages of pregnancy. Present results demonstrated the embryotoxic effect of a single Cd dose. These alterations could be related with placental changes reported in previous works.

(16)

**DETERMINATION OF GLYCOCONJUGATES IN GILLS OF
Steindachnerina brevipinna (Eigenmann & Eigenmann, 1889)**

Díaz AO¹; García AM¹; Lima FB²; Pinheiro Jr C²; Braccini MC²; Guimarães ACG².

¹ Laboratorio de Histología e Histoquímica. Facultad Ciencias Exactas y Naturales. Universidad Nacional de Mar del Plata, Argentina.

² Laboratorio de Histología y Embriología. Pontificia Universidade Católica do Rio Grande do Sul. Campus Uruguaiana. Uruguaiana. Brasil.

E-mail: adiaz@mdp.edu.ar

Glycoconjugates (GCs) are known to have a large variety of functions, from merely mechanical functions, through antimicrobial and antiviral to osmotic functions. In fish the mucous cells are unique in their histological and histochemical characteristics and are influenced by the conditions of the environment and its variations. As a part of our research in the GCs determination on teleosts, the purpose of this work was to analyze the carbohydrates composition in the gills mucous cells of *Steindachnerina brevipinna* of the hydrographic basin of the middle Uruguay River, in Uruguaiana, Rio Grande do Sul, Brasil. The following techniques were employed: 1) PAS: GCs with oxidizable vicinal diols, 2) PA*S: sialic acid and some of their chain variants, 3) KOH/PA*S: total sialic acids, 4) PA/Bh/KOH/PAS: sialic acids residues with O-acyl substitution and O-acyl sugars, 5) KOH/PA*/Bh/PAS: neutral GCs with oxidizable vicinal diols, 6) Alcian blue pH 2.5: GCs with carboxyl groups and/or with sulphate esters, 7) Alcian blue pH 1.0: GCs with O-sulphate esters, 8) Alcian blue pH 0.5: very sulphated GCs. The mucous cells appeared depressed on the surface of the epithelium of the gill archs, the gill rakers and the primary and secondary lamellae. They evidenced neutral and sulphated GCs, together with moderate amounts of GCs with sialic acids. From these histochemical results, it can be concluded that the mucous cells from gills of *S. brevipinna* have some characteristics that are similar to those of other fish gills and they would contribute to cover various functional roles.

(17)
**GLYCANS EXPRESSION OF THE GLYCOCONJUGATES
OF THE MUCOUS CELLS OF
Odontesthes bonariensis (Pisces, Atherinopsidae) GILLS**

Díaz AO¹; García AM¹; Escalante AH²; Goldemberg AL¹.

¹Laboratorio de Histología e Histoquímica.

²Laboratorio de Limnología. Departamento de Biología. Facultad Ciencias Exactas y Naturales. Universidad Nacional de Mar del Plata. Mar del Plata, Argentina.

E-mail: adiaz@mdp.edu.ar

The 'silverside' *Odontesthes bonariensis* is an autochthonous species whose natural distribution corresponds to pampean shallow waterbodies. However, due to its high adaptability and great value for sport and commercial fisheries from warm-temperate Argentinean lakes, it has been introduced in many other geographical areas. The aim of the present work is to determine the pattern of expression of the oligosaccharides residues in the glycoconjugates (GCs) of the mucous cells of *O. bonariensis* inhabiting Los Padres Lagoon by lectin histochemistry. Samples were processed by traditional methods for their inclusion in paraffin. Seven biotinylated lectins were used to identify specific sugar residues of GCs: Con A, WGA, DBA, SBA, PNA, RCA-1 and UEA-1. Primary and secondary lamellae showed the same distribution pattern of lectins in the mucous cells. DBA and SBA presented the maximum reactivity in the mucous cell content while UEA-I had the minimum reactivity, as it was completely negative. WGA, PNA and RCA-I proved to be moderate. Con A showed a weak staining. We conclude that the lectins had a similar behavior in the mucous cells of the primary and secondary lamellae in the gills of *O. bonariensis*. Particularly the monosaccharide galactose was present in greater proportion. It is well-known the importance of the glycosidic residues in the structural and functional attributes of the GCs. In the gills of *O. bonariensis* they would be implied in the prevention of damage to the epithelia, defense against microorganisms and osmotic function in the form of transport of water and ions.

(18)

CALCIFYING ODONTOGENIC EPITHELIAL TUMOR

Dorati P; Mayocchi K; Del Viso S; Micinquevich S.

Patología y Estomatología Clínica, Facultad de Odontología. Universidad Nacional de La Plata. La Plata, Argentina.

E-mail: susmic2003@yahoo.com.ar

The purpose of this study was to report histopathologic and immunohistochemical characteristics of the calcifying odontogenic epithelial tumor (COET), a rare benign neoplasm. Two COET, both of jaw location, were analyzed, one corresponding to a 33 years-old woman, and other to a man of 39 years of age. Conventional histological sections were stained with H&E. For the immunohistochemistry, the peroxide - antiperoxide technique was performed with the following immune sera: *Monoclonal antibody, a mixture of keratin of high and low molecular weight; * Monoclonal antibody for protein S-100 and * Monoclonal antibody for epithelial antigen of membrane, all of them from Biogenex laboratory. Polygonal cells nests with clear cytoplasm and bridges of union were observed in the histological sections. Cells nuclei showed moderated to severe atypical appearance and prominent nucleolus. Amorphous eosinophilic material, amorphous calcifications and other concentric ones (Liesegang's rings) were found. The specimens resulted positive to cytokeratin, protein S-100 and epithelial antigen of membrane. The amorphous material was focally marked for cytokeratin. From the results, we considered that positivity to cytokeratin was coincident with the morphologic cellular picture, specially the presence of intercellular unions, showing that the tumoural cells were of squamous origin. The variable positivity to the immunoserums confirmed the heterogeneity of the tumor. In fact, the COET can appear as a radiological occasional discovery, and can be confused with cysts and other osseous tumors; thus being most important to establish a diagnosis of anatomopathological certainty.

(19)
**MICROSTRUCTURE OF ANTERIOR TEETH ENAMEL:
COMPARATIVE STUDY UNDER SEM**

Durso G; Tanevitch A; Batista S; Abal A; Anselmino C; Licata L.
Facultad de Odontología, Universidad Nacional de La Plata, La Plata, Argentina.
E-mail: gracieladurso@yahoo.com.ar

The aim of this work was to compare the level enamel types in human anterior teeth using longitudinal and cross sections of upper incisive and canines. Two hemi-sections were obtained from each piece, which were then embedded in resin, grinded and etched with acid, metallized and observed under SEM. In the longitudinal-cut samples, both in incisives and in canines, there was evidence of enamel with Hunter Schreger bands (HSB) in the vestibular face in the incisal and medial thirds, which decreased towards the cervical third. Differences of HSB thickness were found among the groups, this being higher in the incisive tooth group. On the outer surface, the radial enamel type was found. In the cervical zone there was a predominance of irregular enamel with prism intercrossed that did not quite form bands, this being more evident in the canines. In the three thirds of the incisive lingual face, enamel with bands in the inner zone and radial enamel in the rest could be observed. In the canines' cervical third the enamel was irregular. For both groups' cross sections, striae of Retzius were described. In the inner zone irregular enamel and prisms were observed in the transverse and oblique sections. In the external zone, the enamel was radial and prisms met the surface in a perpendicular way. The microstructure of both groups did not show significant differences; however, as a consequence of its functional adaptation, the impact zones of occlusal forces showed a higher proportion of enamel with bands.

(20)

C-KIT POSITIVE CELLS IN THE RABBIT'S (*Oryctolagus cuniculus*) STOMACH

Galotta JM¹; Márquez SG^{1,2}; Portiansky EL³; Barbeito CG^{3,4}.

1 Facultad de Ciencias Agrarias, Universidad CA; Ciudad Autónoma de Buenos Aires

2 CBC, Universidad de Buenos Aires, Ciudad Autónoma de Buenos Aires.

3 Instituto de Patología, Facultad de Ciencias Veterinarias, Universidad Nacional de La Plata.

4 Cátedra de Histología y Embriología, Facultad de Ciencias Veterinarias, Universidad Nacional de La Plata.

E-mail: jorge_galotta@yahoo.com.ar

Four types of cells are found in the muscle layers of the digestive system: smooth muscle cells (SMC), neurons, enteric glial cells and interstitial cells of Cajal (ICC). The latter are the pacemakers cells of spontaneous motility in the gut. The goal of this paper was to identify the presence, position and morphometric parameters of ICC in the stomach of rabbit by using immunohistochemical method with CD 117/antic-Kit. Samples of stomach pyloric sections from six three month-old rabbits were included into paraffin and cut in 4 ± 1 μm thick samples. In order to detect these cells LSAB® (DAKO Co.) method was used. The samples were examined under the optic microscope. The morphometry was performed with Image-Pro Plus software. Immunolabeled spindle-shaped cells were detected, as a single cell or in a bundle of them. Their long prolongations were among muscle fibers. In some cases the prolongations extended a certain distance among SMC. In the myenteric plexus long cells were also found, arranged in layers, among the strata of the stomach surrounding the myenteric ganglions. The morphometric values of the immunolabeled cells were: area 17.89 ± 4.23 μm^2 ; major axis: 8.12 ± 1.57 μm ; minor axis: 2.92 ± 0.50 μm ; average perimeter: 18.729 ± 3.33 μm . The obtained results were similar to the reported in previous papers for ICC in other species. Consequently, we were able to conclude that the studied cells are ICC localized in the wall of the rabbit's stomach.

(21)
**VEGF EXPRESSION IN TWO MICE CELL POPULATIONS
ALONG A CIRCADIAN PERIOD**

García AL; Fernández Blanco A; Errecalde AL.

Cátedra de Citología, Histología y Embriología "A". Facultad de Ciencias Médicas. Universidad Nacional de La Plata. La Plata, Argentina.

E-mail: algarcia@med.unlp.edu.ar

The vascular endothelial growth factor (VEGF) is an important angiogenic factor for endothelial cells, expressed in some normal tissues, including brain, kidney, liver and spleen. As it is known that biological systems change with periodicity and that the organism is biochemically different in each time of a circadian period, the objective of the current work was to study the chronobiology of VEGF expression in perivenular hepatocytes and in the kidney tubular epithelia in adult intact male mice. 36 C3HS 90 days-old male mice, standardized for periodicity analysis, were used. They were divided in groups of 5-6 animals each, sacrificed by decapitation and exsanguinations in the following time-points: 04:00, 08:00, 12:00, 16:00, 20:00 and 24:00 hs. During the necropsies the right kidney and the liver triangle lobe were excised and processed for their inclusion in paraffin. The slides were subjected to the immunohistochemical technique for VEGF detection and contrasted with Meyer hematoxylin. Differences among groups with $p < 0.05$ were considered significant. The results showed that at 20:00 hs the VEGF expression values were significantly higher than those of the other time points considered, for both cell-populations. Nevertheless, no significant differences were observed when we compared VEGF values between the hepatocytes and the tubular cells, in the same time point. We concluded that the VEGF expression, in the two analyzed cell-populations, presented a coincident circadian variation, with a peak at 20:00 hs.

(22)

PROLIFERATIVE ACTIVITY IN HEPATOCYTES AND RENOCYTES OBTAINED FROM WEANING AND YOUNG MICE

García MN¹; Andrini LB¹; Inda AM^{1,2}; Furnus CC^{1,3}; García AL¹; Fernández Blanco A¹; Colaci P¹; Errecalde AL¹.
1 Cátedra de Citología, Histología y Embriología A, Facultad de Ciencias Médicas. Universidad Nacional de La Plata. La Plata, Argentina.

2 CIC.

3 CONICET.

E-mail: mngarcia@med.unlp.edu.ar

The presence of grafted tumors modifies the intensity and temporal distribution of DNA synthesis (DNAs), and the mitotic activity (MA) of cellular populations in tumor bearing mice. The purpose of the present study was to analyze the effect of the SS1K hepatocellular carcinoma cells injection on DNAs and MA of hepatocytes and renocytes. The mice (21 days old) were divided into two groups: 1) control and 2) mice injected with 0.2 ml of tumoral suspension on the day 15 of life. The sacrifice of the animals was performed on the day 21 at 00:00 and 16:00 hours in both groups. The samples were processed as follows: one half with the immunohistochemistry technique using bromodeoxyuridine, and the other half with statmokinetic method. The DNAs and the MA indexes were determined for each animal studied and the $X \pm SE$ were established either for each lot and group. The data were analyzed with Student's *t* test. The results showed that, hepatocytes and renocytes DNAs indices were significantly lower in group 2 than in the control group. The MA indices were significantly lower in renocytes in the group 2 than in the control group but in hepatocytes only at 00:00 h. It could be argued that the carcinoma presence alters the proliferation process in the cellular populations studied.

(23)

DENTAL HOMOLOGIES OF THE TERTIARY SOUTH AMERICAN UNGULATES

Gelfo JN.

Departamento Científico Paleontología Vertebrados, Museo de La Plata.. La Plata, Argentina. CONICET

E-mail: jgelfo@fcnym.unlp.edu.ar

The right identification of the primary tooth homologies is one of the major difficulties to understand the phylogeny of the extinct Notoungulata, Litopterna, Astrapotheria, Pyrotheria and Xenungulata. All the specific taxa are defined based on dental characters, but different names have been used for homologous characters, as well as the same denominations for non-homologous ones. In this work the fit between commonly used dental nomenclature and the concept of homology was discussed. Representative remains of lower molars of these orders were analyzed applying the similarity and conjunction criteria. The characters discussed here are: protolophid and protocristid, used respectively for the lophid and cristid than join together protoconid and metaconid; metalophid, often used as synonym of protolophid but also for other structures; paralophid and paracristid, defined for the lophid and cristid extended mesio-lingually from the protoconid; hypolophid, for the lophid that joins hypoconid and entoconid, but excluding the hypoconulid; entolophid, for the lophid extended from entoconid to cristid obliqua mesial to the hypoconid; and paraconid and neoparaconid, for the cusp mesial to the metaconid. From the present analysis it could be concluded that the homonyms and heteronyms for lophids and cristids should be avoided. Tooth accidents should be nominated primarily following a topographic criterion, so that definitions do not contradict the Cope and Osborn proposal. New names should only be used after a phylogenetic analysis, considering that topographic similarity may correspond to a homoplastic character and without previous assumptions of direction of evolutionary change.

(24)

**EPONYMS IN MORPHOLOGICAL SCIENCES TEACHING AND
LEARNING I: EPONYMS AND HISTOLOGY TEXTBOOKS**

González NV^{1,2}; Barbeito CG^{2,3}.

1 Cátedra de Histología y Embriología Animal, Facultad de Ciencias Naturales y Museo.

2 Cátedra de Histología y Embriología, Facultad de Ciencias Veterinarias.

3 Cátedra de Patología General, Facultad de Ciencias Veterinarias, Universidad Nacional de La Plata. La Plata, Argentina.

E-mail: nvgonzal@hotmail.com

An eponym is a word derived from the name of a person or a place that designates some organ's part, a period, an illness, a unit, etc. Morphological sciences employ many eponyms; i.e. Golgi apparatus. We have taken eponyms as a nucleus for an investigation plan which includes three aspects: 1) eponyms and Histology textbooks; 2) eponyms and professors' discourse, and 3) eponyms use and valuation by students and professors. In this communication we report the findings involving the first approach. For that purpose we analyzed three Histology textbooks (Fawcett, D. (1997); Geneser, F. (2000), and Ross, M. *et al.* (2004) from now on designated as textbook 1, 2 and 3, respectively). Text and images for compact bone tissue and liver were assessed, employing a terminology technique analysis. The comparison for compact bone tissue showed that, in a global analysis, texts 1 and 2 utilize fewer eponyms and synonyms than text 3. In contrast to this, when eponyms' use for liver structures was assessed, the divergent use found made generalizations difficult. Our study showed quantitative and qualitative differences in the use of synonymous and eponyms in these three texts. We believe that these differential characteristics do not diminish the book's quality but that rather reflects the conceptions of the authors on learning, functions of texts and, although less explicitly, on reading comprehension and on the discourse structure in written communication. Finally, some implications for the teaching and learning of Histology in relation to eponyms use are discussed.

(25)
**NEW SPECIES OF *Helobdella* (HIRUDINEA, GLOSSIPHONIIDAE)
FROM PATAGONIA, ARGENTINA**

Gullo BS.

Cátedra Zoología Invertebrados I, Facultad de Ciencias Naturales y Museo, Universidad Nacional de La Plata,
La Plata, Argentina.

E-mail: bgullo@fcnym.unlp.edu.ar

Glossiphoniidae is a cosmopolitan family of freshwater leeches (Hirudinea) composed of 23 genera, with representatives found in all continents except Antarctica. There are over than 30 described *Helobdella* species from South America. The recent synonymies of other Glossiphoniidae genera increase that number to approximately 40 species. The new freshwater leech species *Helobdella* is described based on the examination of 12 specimens collected in Laguna Fantasma, Bariloche (41° 05'S 71° 28'W), during December 2002. Leeches were found attached to submerged plants. They were relaxed with gradual addition of 70% ethanol, fixed in 10% formalin, stored in 70% ethanol and stained with borax carmine. Diagnostic characters are: body thin and lanceolate; annuli not subdivided dorsally; neither nuchal scute nor glands present in VIII; dorsum surface lacking both papilla and tubercles; one pair of eyes on somite II/III; mouth pore in the anterior margin of the oral sucker; proboscis base at XII/XIII; diffuse salivary glands; oesophagus simple; crop without gastric chambers, digitiform caeca and postcaeca; intestine with four lobes. Six pairs of spherical testisacs; sperm ducts reach back to somite XV. Pyriform atrium without preatrial loops. Simple ovisacs, reaching XIII. Regarding the diagnosis of the genus *Helobdella*, members of the genus present gonopores separated by one annulus, one pair of cephalic eyespots; neither oesophageal organs nor mycetomes are present; none known to be sanguivorous on vertebrates, triannulate somite. These characteristics are consistent with the species described herein showing clearly that this species is definitively a *Helobdella*.

(26)

**COMPARATIVE STUDY OF THE HAMULAR FURROW DIMENSIONS
IN TOOTHED AND TOOTHLESS HUMAN CRANIUMS**

Irigoyen S; Abilleira E; Segatto R; Bustamante C; Mancuso P; Fingermann G; Delocca M; Mazeo D.
Facultad de Odontología, Universidad Nacional de La Plata. La Plata, Argentina.
E-mail: carlosbustamante1000@yahoo.com.ar

The hamular or pterygopalatine furrow is an anatomical accident located in the upper jaw. From the clinical point of view this structure appears as a cross-sectional furrow that constitutes the external portion of the line of postdamming (protetic area rear boundary of the superior maxilla). With the arrival of the implantology it has received greater attention for its use in the pterygoid implant technique. In this communication we present the comparison of this furrow's dimensions between toothed and toothless craniums. Two hundred craniums (80 toothed and 120 toothless) were used to measure, with a digital caliper, the distance between internal and external ends of the furrow. Measures were expressed in mm. The statistical analysis was performed considering global data for toothed and toothless craniums. For the toothed craniums the following results were found: arithmetic mean=7.58; mode=7.22; median=7.57; rank=4.77 and standard deviation=1.02 whereas for the toothless craniums the results were: arithmetic mean=6.90; mode=7.57; median=6.98; rank=3.62 and standard deviation=0.58. Values concerning global analysis were: arithmetic mean=7.24; mode=7.57; median=7.27; rank=4.77 and standard deviation=0.30. On the basis of the obtained results it can be concluded there were no significant differences between both groups. In the toothless craniums a small relevant diminution in the length of the furrow could be appreciated.

(27)

**PTERYGOPALATINE FURROW'S DIMENSIONS IN
TOOTHLESS HUMAN CRANIUMS**

*Irigoyen S; Abilleira E; Segatto R; Bustamante C; Mancuso P; Fingermann G; Delocca M; Mazeo D.
Facultad de Odontología, Universidad Nacional de La Plata. La Plata, Argentina.
E-mail: carlosbustamante1000@yahoo.com.ar*

The pterygopalatine furrow is an anatomical accident located in the alveolar apophysis' posterior extremity of the superior maxillae. Much attention has been paid to this bony structure with the development of dental implantology particularly for the implementation of the technique known as pterygoid implant. In the present work the determination of the pterygopalatine furrow dimensions in adult toothless human craniums was performed. For that purpose the distance between internal and external ends of the furrow was measured in 120 experimental units, employing a digital caliper. Measures were expressed in mm. The statistical analysis was performed considering side of the registry and global data. The following results were obtained: a) for the right side: mean=7.09; mode=7.84; median=7.13; rank=3.62 and standard deviation=1.30. b) For the left side: mean= 6.70; mode=7.57; median=6.83; rank=3.62 and standard deviation=1.38. The global analysis results were: mean=6.90; mode=7.57; median=6.98; rank=3.62 and standard deviation=0.58. On the basis of the obtained results it can be concluded that no significant differences between the right and the left sides of the pterygopalatine furrow were found.

(28)

INTERPRETATION OF THE NUCLEAR MAGNETIC RESONANCE IMAGEN OF THE CRANIOMANDIBULAR ARTICULAR COMPLEX

Mancuso P; Caserío J; Castagno L. Collaborators: Abilleira E; Fingermann G; Viscovick C. Cátedra de Anatomía, Facultad de Odontología. Universidad Nacional de La Plata. La Plata, Argentina. E-mail: mancusopablo@hotmail.com

Nowadays, the magnetic resonance (MR) stands out like one of more reliable methods for the study of the anatomic-functional alterations of the craniomandibular articular complex (CMAC). Nevertheless, this study interpretation is often difficult for the general odontologist, due to the lack of knowledge respect to its technical aspects. For that reason, our intention was to establish a detailed order as far as the accomplishment of the procedure, considering positioning of the patient, acquired sequences and flat of cut; all variables that we considered elementary for a better understanding of CMAC by MR and their correlation with clinical-pathological antecedents, that can help the dentistry professional to achieve a correct diagnosis by images. The first coils were developed in 1984 for the specific study of the CMAC, considering MR nowadays a routine method for the study of this articular complex. Its main characteristic is the non-invasive visualization of the soft components and the internal alterations of the articular disc, allowing the study in different planes (coronal, axial and sagittal). We propose then the following three step protocol for the interpretation of the MR images of the CMAC. First step consists in the visualization and analysis of the cortical, medullar and cartilage areas. The second step involves the analysis of the articular disc position and structure whereas the third step includes the analysis of the temporal-disc and mandibular-disc articular spaces, and finally the structure of the ligament system.

(29)
**INMUNOHISTOCHEMISTRY CD-117/ANTI C-KIT
IN THE BOVINE RUMEN**

Márquez SG^{1,2}; Galotta JM¹; Portiansky EL³, Barbeito CG^{3,4}.

1 Facultad de Ciencias Agrarias, UCA.

2 CBC, UBA.

3 Instituto de Patología, Facultad de Ciencias Veterinarias, Universidad Nacional de La Plata.

4 Cátedra de Histología y Embriología, Facultad de Ciencias Veterinarias, Universidad Nacional de La Plata.

Freire 183. CP1426. Buenos Aires.

E-mail: smarquez@ciudad.com.ar

The interstitial cells of Cajal (ICC) are involved in the regulation of the contractions of the wall of gastrointestinal tract. The ICC are arranged in a three-dimensional net that connects the neurons of the myenteric plexus to the smooth muscle cells (SMC). Our team has reported this finding in different sections of the bovine's digestive system. In this communication we inform about the research of the presence, distribution and morphometric values of the ICC in bovine rumen. Samples from six Hereford healthy adult cows were obtained from commercial abattoir and included into paraffin. The immunohistochemical technique was carried out with the choice antibody for ICC, CD117/antic-kit. LSAB® from DAKO Co. was employed as detection method. The samples were examined under optic microscopy. The morphometric analysis was realized by Media Cybernetics Image-Pro Plus software. Positive c-kit cells were identified throughout the muscle layer. These cells were uniformly distributed and their cellular density was 4.26 ± 1.53 cells/ $10^4 \mu\text{m}^2$. We found spindle-shaped cells whose thin irregular extensions extended among SMC and contacted the neighboring positive cells with their tips. The morphometric parameters of the labeled cells were: area: $96.68 \pm 16.93 \mu\text{m}^2$; mayor axis: $22.74 \pm 3.52 \mu\text{m}$ and minor axis: $5.56 \pm 0.62 \mu\text{m}$. The positive immunolabeling, their localization and cell shapes as well as the extensions pattern distribution allowed us to conclude that the investigated cells are ICC for having the characteristics described in previous reports.

(30)

TUMORAL GRADE, SIZE AND REACTIVITY FOR VASCULAR ENDOTHELIAL GROWTH FACTOR (VEGF) IN BREAST CARCINOMAS

Martín C^{1,2}; Corrons F¹; Colaci P¹; Marini J^{1,2}; Errecalde AL¹.

1 Cátedra "A" de Citología, Histología y Embriología, Facultad de Ciencias Médicas, Universidad Nacional de La Plata. La Plata, Argentina.

2 Servicio de Patología, HZGA San Roque. Gonnet, Argentina.

E-mail: drcmartin@speedy.com.ar

Classical prognostic factors of breast carcinomas include axillary lymph node status, tumoral size and cyto-architectural grade added to mitotic activity (Nottingham score). Recently, several studies have focused on angiogenesis in breast cancer, searching for its probable prognostic significance and, at the same time, evaluating the use of target therapies to diminish vascular tumoral density. In this retro- and prospective study, we examined the expression of VEGF in 60 cases of infiltrating breast ductal carcinomas. The greater macro-microscopic diameter was determined in each tumor. Histological sections were stained with H&E for cyto-histological grading and mitotic count. Parallel sections were placed in positive-charged slides and subjected to epitope retrieval with citrate buffer in a microwave oven (2x15 min) and incubated with anti-VEGF mouse monoclonal antibody (C1, 1/80, Santa Cruz, Ca., USA). The detection was done with Envision (Dako) and DAB as chromogen. Of the 60 cases, 16 were grade 1, 22 grade 2, and 22 grade 3. Tumoral diameter for each grade was 1.9 cm, 2.4 cm and 3.3 cm, respectively. VEGF immunoreactivity was observed in 28 out of 58 evaluable cases. The reactivity according to grade was: G1=37.5%, G2=54.5 and G3=45.4%. Differences among tumoral diameters by grades were statistically significant ($p < 0.05$). No differences were found between VEGF expression and the other variables studied. Our results showed that nearly 50% of breast ductal carcinomas express VEGF, being candidates for Bevacizumab antiangiogenic therapy. The biological meaning of the findings requires complementary studies with vascular microdensity measurement.

(31)

***Rothia dentocariosa* STUDY IN THE SUPRAGINGIVAL PLAQUE**

Martínez C; Obiols C; Friso E; González AM; González A; Escudero Giachella E; Oviedo Arévalo J.
Cátedra Microbiología y Parasitología, Facultad de Odontología, Universidad Nacional de La Plata. La Plata, Argentina.

E-mail: cristes@fibertel.com.ar

Rothia dentocariosa is a Gram positive bacteria; it may be coccoid, filamentous and sometimes has a diptheroid aspect. It is aerobic and some strains can develop under anaerobic conditions. They are about 1.0 to 1.5 nm in coccoid forms and between 1 - 5 nm in length by 1 nm in width for diptheroid and filamentous forms. These microorganisms are common in the oral cavity, have no mobility, their asexual reproduction is binary, not forming spores. For his study were selected in 70 patients at the Faculty of Dentistry of La Plata. Samples of supragingival plaque and carious lesions, using standard appropriate instrumental were taken. The samples were cultured in soy trypticase broth and then inoculated in agar plates with trypticase soy medium in aerobic conditions at 37 ° C. The bacterial growth was clearly evidenced by the presence of colonies of microorganisms on the surface of agar: white creamy, rounded or convex shape, opaque, smooth or slightly rough with approximate sizes between 1 and 4 mm in diameter. From colonies suspected, biochemical tests were conducted to identify these strains as belonging to *R. dentocariosa*. The results showed their presence in supragingival plaque (18%) and in carious lesions (9%). According to this study *R. dentocariosa* is a bacterium which is found more frequently in supragingival plaque than in carious lesions.

(32)

LASER REMOVAL OF THE SMEAR LAYER

Milat E; Etchegoyen L; García Gadda G; García Gadda B; Cantarini M; Basal R.
Facultad de Odontología, Universidad Nacional de La Plata. La Plata, Argentina.
E-mail: cocamilat@yahoo.com.ar

The success of the endodontic treatment consists of a rigorous cleaning of the affected dental piece's radicular conduits, removing the smear layer that is produced after its instrumentation. In the present work, the removal of the smear layer was performed with Erbium: YAG laser for the characteristics that it presents. It was applied to forty out of eighty just removed dental pieces, selected according to clinical and radiographic criteria. The pieces were divided into four groups and received the following treatments. First group: extirpation of the dental pulp and washing with sodium hypochlorite and lime water. Second group: the same procedure as in the first group was applied plus instrumentation with files. Third group: besides the last procedure, the Erbium: YAG laser (160 Mj; 15Hz) was used, introducing the fiber inside the radicular conduit and withdrawing it 1 mm from the conduit's apical constriction. Fourth group: the same procedures than to the third group was applied, but 140 Mj and 15 Hz were employed. After procedures dental pieces were metallized to turn conductive their surface and observed under the scanning electron microscope. It could be seen that the biggest part of the smear layer had been removed according to the power used, and the little dentinary conduits were clean and open as well in the root's third middle as in the apical third. The smear layer produced by the instrumentation must be removed, and best results were obtained by using the Erbium: YAG laser.

(33)

**MYOSKELETAL SPECIALIZATIONS FOR DIGGING IN THE RODENT
Lagostomus maximus (CAVIOMORPHA, CHINCHILLIDAE)**

Morgan CC; Olivares AI; Alvarez A; Verzi DH.

División Zooloía Vertebrados, Sección Mastozoología, Museo de La Plata. Universidad Nacional de La Plata. La Plata, Argentina.

E-mail: cmorgan@fcnym.unlp.edu.ar

The plains viscacha, *Lagostomus maximus*, is a South American rodent which builds extensive colonial burrow systems. We evaluated digging specializations of this species through dissection of the jaw and forelimb muscles, and quali-quantitative analysis of associated skeletal characters. Functionally significant indexes were calculated and compared with those from other caviomorphs with diverse habits, and analyzed by Principal Components Analysis (PCA). The *temporalis* and *masseter medialis infraorbitalis* muscles, linked to vertical mandibular forces, were greatly developed. *M. masseter lateralis* showed subhorizontal fibers. *M. masseter posterior* was very poorly developed. Comparatively, the subterranean *Ctenomys* (Ctenomyidae) showed good development of the latter muscle, as well as hypertrophied *m. masseter lateralis* with nearly vertical fibers. *Chinchilla* (Chinchillidae, epigeal) showed little development of these muscles. In the arm of *L. maximus*, *m. triceps brachii* was extremely well developed; in particular, its long head presented three parts with differently-oriented fibers, which suggests great force production during forearm extension. Hand flexor muscles were less developed than those of *Ctenomys*. PCA segregated genera from epigeal to subterranean habits, and clustered *Lagostomus* with other fossorial genera by its mandibular and incisor width, procumbency and orbital size. Myological features associated to postcranium agreed with the distalized deltoid process, large humeral epicondyles and well developed olecranon, which set *Lagostomus* apart from other chinchillids and closer to *Ctenomys*. These results show that *L. maximus* has moderate myoskeletal specializations for digging in both forelimb and head; these could be associated to a dual digging strategy, mainly scratch-digging but with some use of incisors.

(34)

**PRELIMINARY STUDY ON THE EFFECTS ON JUVENILE
PEJERREY *Odontesthes bonariensis* EXPOSED TO MALACHITE GREEN**

Pacheco Marino SG¹; Plaul SE²; Andrés Laube PF²; Barbeito CG^{1,2}; Salibián A^{3,4}.

1 CONICET.

2 Cátedra de Histología y Embriología, Facultad de Ciencias Veterinarias Universidad Nacional de La Plata.

3 CIC Prov. Bs. Aires.

4 PRODEA, Departamento de Ciencias Básicas, Universidad Nacional de Luján.

E-mail: suani.pm@gmail.com

The objective of the present work was to obtain some preliminary knowledge of the Malachite Green (MG) effects on juvenile pejerrey *Odontesthes bonariensis* (Valenciennes, 1835). In order to perform the toxicological trials, 39 days of age specimens were used. Semi-static bioassays with daily renewal of the media were performed; the temperature was kept constant at 17 °C and the photoperiod was natural. Four MG concentrations were tested [0.0 (controls), 0.1, 1.0 and 10.0 ppm]. The MG solutions were prepared with reconstituted US EPA hard water (pH: 7.6-8.0; hardness 160-180 mg CaCO₃/L; alkalinity: 110-120 mg CaCO₃/L). Five individuals were incubated in each solution. Survival was recorded every 24 hours, during two days. At the end of the assays fishes were fixed in phosphate-buffered formaldehyde. A 100% mortality was observed at the highest concentrations (1.0 and 10.0 ppm) after 24 hs. After 48 hs exposure no mortality was registered in the group exposed to 0.1 ppm as well as in the control group. The histopathological analysis of the samples showed that the liver was the most affected organ by MG at 1.0 ppm; degenerative lesions were found in some of the individuals which appeared spread to the whole organ. We concluded that under our experimental conditions the toxic effect is dose-dependent; the highest concentration of MG resulted lethal for juvenile pejerrey.

(35)

APENDICULAR MIOLOGY OF *Rhea americana* CHICKS (Greater Rhea)

Picasso MBJ.

División Paleontología Vertebrados, Museo de La Plata. Universidad Nacional de La Plata. La Plata, Argentina.

E-mail: mpicasso@fcnym.unlp.edu.ar

The Greater Rhea (Aves, Rheidae) is a South American endemic Paleognathae bird. Due to the cursorial locomotion, the posterior locomotor module shows a great development. So, the purpose of this work was to analyze the changes that take place in the hindlimb muscles during the postnatal development. In this preliminary analysis a sample of ten chicks of *Rhea* between three and 15 days of age and one adult female had been studied. The individuals came from a breeding farm of *Rhea americana*. The body mass of each individual and each hindlimb muscle (wet weight) was taken with 1 g and 0.01 g of precision respectively and averaged. The chicks weighed 364.88 g, and the adult female 19.300 g. Two muscles showed differences with age: *obturatorius medialis* in the adult reached a 39% of weight of all muscles studied whereas in chicks just the 4%. *Iliotibialis lateralis* showed greater mass in chicks (23%) than in the adult (14%). The remaining muscles contributed in similarly account in both adult and chicks. These differences between chicks and adult would be related with a dissimilar locomotion way through postnatal life. This present work is part of a wider research that pretends to determinate the growth pattern, the functional morphology and the evolutive implications of the hindlimb muscles of Rheidae. The study of a larger sample of different ages will contribute to complete the growth and transformation pattern.

(36)

**BRAIN ANATOMY OF A FOSSIL EAGLE
(FALCONIFORMES, ACCIPITRIDAE, BUTEONINAE)***Picasso MBJ¹; Tambussi C^{1,2}.**1 División Paleontología Vertebrados, Museo de La Plata. Universidad Nacional de La Plata. La Plata, Argentina.**2 CONICET, Proyecto PIP 5694.*E-mail: mpicasso@fcnym.unlp.edu.ar

The presence of a Falconiform *calvaria* (MPEF-PV 2523, Museo Paleontológico Egidio Feruglio) referred to the Accipitridae Buteoninae (eagles) was recorded in late Miocene sediments of the Chubut Province of Argentina. From this bone remain a silicone rubber endocast which reflects almost completely the dorsal morphology of the brain was obtained. In this brain cast is was possible to recognize the pear shaped *hemispherium telencephali*, which were separated by the *fissura interhemisferica*. The *eminentiae sagittalis* were moderately developed and separated from the remaining telencephalum by soft and shallow *valeculae*. The *tectum mesencephali* are transversally elongated respect to the sagital plane. The *cerebellum* showed laterally the two prominences: the *auriculae cerebelli*. Also some blood vessels could be identified in the endocast. This eagle brain would belong to the 'neural generalist' cerebro-type. This category does not show the preeminence of any brain structure. This group includes the Falconiform and other birds, no phylogenetically related, but shearing with them similar ecology and behavior. This new discovery should be highlighted, because (1) the possibility to study endocast of extinguished birds is particularly unusual, due to the scarcity of well preserved skulls; (2) the endocast provides important new evidence to analyze the phylogenetic relationship of Aves; (3) offers new data to do inferences related to behavior and ecology, based in the size and relative development; (4) the actual knowledge of the Buteoninae brain does not yet allow a comparison of the neural morphology, to quantify the brain variability and their transformation patterns.

(37)

STOMACH AND OESOPHAGUS HISTOLOGY OF DORADO *Salminus brasiliensis* CUVIER, 1816 (PISCES: CHARACIFORMES). A PRELIMINARY STUDY

Plaul SE¹; Andrés Laube PF¹; García Romero N²; Barbeito CG^{1,2}.

¹ Cátedra de Histología y Embriología.

² Cátedra de Patología General Veterinaria. Facultad de Ciencias Veterinarias. Universidad Nacional de La Plata. La Plata, Argentina.

E-mail: splaul@museo.fcnym.unlp.edu.ar

Due to its commercial and sport interests the dorado *Salminus brasiliensis* (Characiformes) is one of the most important fishes in Argentina. Our objective was to describe the histological structure of his fish. Five to 7,9 Kg adult fishes were collected from the Paraná river. Stomach (anterior, middle and terminal portion) and oesophagus samples were excised and processed for paraffin inclusion and H&E staining. Mucosa, muscular and serosa tunics were observed. Oesophagus mucosa folds have a stratified epithelium with mucous and acidophilic granular cells. Corium connective tissue varies being dense around muscular tunic. Muscular tunic has two striated muscle layers: an inner longitudinal one, and an outer circular one. Stomach mucosa presented branched folds with a columnar cells single layer. Transition portion between oesophagus and stomach showed branched tubular glands. Size and number were increased in the stomach. These glands were surrounded by connective tissue with muscle fibbers. Muscular arrangement was irregular; however three smooth muscle layers could be described: an inner one with longitudinal arrangement, a middle circular one and an outer longitudinal one. Transition portion presented differences: an inner and middle striated muscle layers and outer smooth muscle layer. Serosa tunic was composed by loose connective tissue, adipose cells, dense connective tissue and mesothelial squamous epithelium. The histological structure of these organs is similar to other teleost fishes, but presented some differences associated with its nutritious habits. The knowledge of the dorado digestive histological structure cooperates with pathology studies, aquaculture development and a better management of natural resources.

(38)

**AGE COMPARISON BETWEEN PROF. DR. RÓMULO LAMBRE COLLECTION
AND THE DEATH DATA OF ARGENTINA**

Plischuk M^{1,5}; Desántolo B^{4,7}; García Mancuso R⁵; Salceda S^{1,5}; Costi D⁴; García M²; Laguens M³; Paggi R²; Maliandi N¹; Prat G⁴; Errecalde A²; Inda A².

1 Cátedra de Métodos y Técnicas en la Investigación en Antropología Biológica, FCNyM, UNLP.

2 Cátedra de Citología, Histología y Embriología "A", FCM, UNLP.

3 Cátedra de Patología "B", FCM, UNLP.

4 Laboratorio de Investigaciones Morfológicas Aplicadas. Calle 60 y 120 FCM, UNLP.

5 CONICET.

6 CIC.

7 UNLP.

E-mail: mplischuk@fcnym.unlp.edu.ar

The osteological collection Professor Dr. Rómulo Lambre comprises 230 both sexes human skeletons of known age. Those remains were provided to the School of Medicine by the La Plata County Cemetery. The construction of any osteological collection may be biased in the sample composition. The variables that may bias the collection start at the moment of the death, with the decision in the manner of treats the body, the place chosen to burry the death and personal or familiar claims. Our aim was to determine if those variables bias the collection age distribution, confronting that with the information about the deaths occurred in the whole country. Since 1995 was the year most represented in our collection, the same year of the national survey was chosen to confront our sample. To make these comparisons we discriminated 10 age groups (0-11 months, 1-4, 5-14, 15-24, 25-34, 35-44, 45-54, 55-64, 65-74, 75 + years). After that we calculated how many individuals of our sample were in each group, and finally we compared this information to data from the Statistics and Information Direction of the National Health Ministry. The results showed a similar distribution for both groups under study, so we could conclude that our collection reflects the mortality of the country.

(39)

TRACHEAL IRRIGATION: ITS ANATOMIC-SURGICAL RELEVANCE

Prat G; Costi D; De Simone R; Schlain S; Miquelini LA; Castilla S.

Laboratorio de Investigaciones Morfológicas Aplicadas. Cátedra de Anatomía "C". Facultad de Ciencias Médicas, Universidad Nacional de La Plata. La Plata, Argentina.

E-mail: gprat@atlas.med.unlp.edu.ar

An anatomical dissection of the trachea in its cervical portion with special approach of vascular pedicle was performed. Ten both sexes-formolized pieces were dissected and 10 clinical cases of patients that underwent a surgery were analyzed. In 5 out the 10 formolized pieces, a medial incision affecting the tracheal region was made to identify laterally the vascular pedicles. In the remaining pieces the surgical dissection of the cervical trachea was performed releasing completely the organ, respecting the lateral faces and preserving the tracheal vascular nutrition, approaching the cervical structures by this incision. In the 10 clinical cases, corresponding to patients with tracheal pathology surgery, the complete approach of the cervical trachea was made. In the cadaveric pieces' dissections we individualized the adjacent vascular and anatomical elements to avoid injuries of noble elements. In the surgical procedures the medial access demonstrated that it successfully allowed the resection of the tracheal pathology and the identification of the tracheal vascular elements, and the relation with the anatomical elements that surround it. Therefore, the access employed in surgical patients proved to be of singular importance in the resolution of frequent tracheal pathologies, preserving vascular elements as well as the great cervical blood-vessels, adjacent structures and organs.

(40)

**LECTINHISTOCHEMISTRY IN THE SOW ENDOMETRIUM
ALONG THE REPRODUCTIVE CYCLE**

Sant'Ana FJF¹; Nascimento EF²; Andrés Laube PF³; Gimeno EJ³; Barbeito CG³.

1 Universidade Federal de Goiás/Campus Jataí, Jataí, Brasil.

2 Escola de Veterinária, Universidade Federal de Minas Gerais, Belo Horizonte, Brasil.

3 Facultad de Ciencias Veterinarias. Universidad Nacional de La Plata. La Plata, Argentina.

E-mail: barbeito@fcv.unlp.edu.ar

Uterine secretions play very important roles in the interactions between uterus and early developmental conceptus. The carbohydrates are involved in these functions. In the present work, the sacharides pattern was compared in the normal uterus of sows during the ovarian cycle using lectin histochemistry. The following biotinylated lectins were used: Con A, DBA, SBA, PNA, RCA - I, UEA-1 and WGA. The uterine structures examined were: glycocalix and apical surface of luminal and glandular epithelium and connective tissue. Glands were divided in three sectors: luminal (neck), middle (body) and deep (bottom). Glycoconjugate labeling showed some scarce differences between phases of ovarian cycle. Con A labelled more intensely the glandular epithelium in the luteal phase, in comparison with follicular phase. SBA glandular labelling showed sectorial differences in the glandular binding in the luteal phase. Connective tissue was positive only to RCA-1 and WGA lectins in all the sows. WGA binding was stronger in the luminal epithelium while labelling in the glandular epithelial cells was mild to absent. Taking into account these lectin labelling, apical surface coat (glycocalyx) and apical cytoplasm of the luminal and glandular uterine epithelium express a variety of terminal sugar residues, including α -D-mannose, α -D-glucose, α -D-N-acetyl-galactosamine, α -D-galactose, α -L-fucose and α -D-N-acetyl-glucosamine. The cycle changes were minor than the previously found in the oviduct of sows. These results are only partially similar to the previously reported; these variations could be originated from age and strain differences.

(41)

**CLEANING TECHNIQUE FOR SCANNING ELECTRONIC MICROSCOPY:
ITS APPLICATION IN GORDIIDA (NEMATOMORPHA)**

Sarmiento P^{1,2}; De Villalobos C^{1,3}; Zanca F^{1,2}.

1 Servicio de Microscopía Electrónica, Facultad de Ciencias Naturales y Museo. Universidad Nacional de La Plata. La Plata, Argentina.

2 CONICET.

3 CIC.

E-mail: fmzanca@fcnym.unlp.edu.ar

The Gordiida are entomopathogen. During their adult life they live in freshwater. For their determination, two sets of characters are used: the structures of cuticle and the posterior body end. The cuticle can be smooth or very ornamented, being possible to observe cuticular elevations (areoles), pores and tubercles, of different lengths and distribution. In regard to the environments these animals live in, it is frequent to find vegetal materials, dirt, bacteria and diatoms on their body surface. The observation of the ultrastructural details can be masked by all these elements and the secretions the worms produce. Here we offer a new technique for the cleaning of these worms. Cross sections of the midbody region of two species (*Chordodes kolensis*, *Noteochordodes achosmosus*) were made. The new technique consists of making 3 washings with CLINIQUE, a commercial rinse-off eye makeup solvent (2 drops in 1.2ml distilled water). For each of these washings an ultrasonic US-500D was used. Each washing was followed by rinsing with distilled water. These pieces were mounted following the habitual techniques for SEM observation. For comparisons, fragments of these specimens were washed three times with distilled water only. In all cases, the observation was made in a SEM JEOL JSM 6360LV. Results showed that ultrastructural details were better observed in the commercial rinse-treated material.

(42)

APPLICATION OF THE BACTERIAL PLAQUE INDEX

Tosti S; Baudo J; Domínguez G; Cecho A; Penalva M; Sambartolomeo P.
Facultad de Odontología, Universidad Nacional de La Plata. La Plata, Argentina.
E-mail: sobetis@yahoo.com.ar

The objectives of the present work were 1) to determine the incidence of the gingival disease in adolescents, for the instrumentation of educational and preventive rules and 2) the evaluation of the preventive rules' impact in adolescents. The sample comprised 100 students, aged 14-18, from one Polimodal level school in Ensenada city. We used the Silness and Loe plaque index (PI), which recognizes four stages: degree 0 for no plaque; degree 1 as evidence of the presence of a thin plaque film in contact with the gingival edge; degree 2 for a moderate plaque all along the gingival edge and degree 3 for important plaque accumulation all along the gingival edge and interdental spaces. The work was done in two periods of time during 2006. In the first period (April-May) gingival appearance was monitored and results were: 14%; 24%; 43%, and 19% for degrees 0, 1, 2 and 3, respectively. A preventive program was implemented for the second period (June, August and September) with students attending brushing technique classes. In November, when preventive rules had been set into practice, the PI results were: 22%; 38%; 31%, and 9% for degrees 0, 1, 2 and 3, respectively. These values indicated us a high gingival disease incidence in these adolescents due to bacterial plaque but also that the practice of adequate preventive rules, these results could be reverted.

(43)
**GINGIVITIS RESEARCH IN FIRST TRIMESTER PREGNANT
AND LYING-IN WOMEN**

Tosti SB; Baudo JE ; Dominguez GE; Di Salvi N; Allegretti PE.

Cátedra de Fisiología, Facultad de Odontología. Universidad Nacional de La Plata. La Plata, Argentina.

E-mail: sobetis@yahoo.com.ar

During pregnancy many changes occur in the oral cavity. The most frequently manifestation is gingivitis. Deficient oral hygiene, hormonal and vascular modifications, increases seriously the response to local irritants. Progesterone levels increase has a direct effect over gums microvascularization. The present research had the purpose of evaluation of gingival inflammation in groups of pregnant women during the first trimester of their pregnancy of lying-in women. The group comprised 40 women between 18 and 30 years-old; 20 of them were between 8 and 13 weeks of pregnancy under control and normal developing and 20 were within 60 days post-birth and had had a normal parturition. The gingival inflammation index (Silness and Loe, 1963) was determined. According to Silness and Loe the values for mild inflammation are between 0.1 and 1.0 and for the moderate inflammation between 1.1 and 2.0. The totality of the pregnant presented gingivitis (62.3% mild level; 37.7% moderate level). Mild gingivitis was detected in 83.4% of lying-in women whereas 16.6% showed moderate gingivitis. The obtained results seemed to demonstrate that gingivitis during pregnancy must not be attributable only to the bacterial plaque increase. It is suggested that the edema and gingival bleeding which is observed during pregnancy may be induced by an increase of the hormonal levels in plasma.

(44)

**RAT EPIDIDYMAL HISTOLOGY AND LECTINHISTOCHEMICAL STUDY
ALONG AGES IN RATS INJECTED WITH ALLOXAN AT POSTWEANING**

Vázquez SMV¹; Hisano N¹; Barbeito CG^{2,3}.

1 Cátedra de Histología y Embriología, Facultad de Ciencias Médicas, Universidad Nacional de Rosario.

2 Cátedra de Histología y Embriología; Instituto de Patología; Facultad de Ciencias Veterinarias, Universidad Nacional de La Plata.

3 CONICET.

E-mail: silvievaz@hotmail.com

Alloxan can induce type I diabetes in animal models. The present study analyzed the morphology and pattern of lectin binding of rat epididymis. At postweaning 20 rats of the "m" strain were injected with alloxan (24 mg/100 g of body weight) (group A) and 16 rats of the same strain were injected with distilled water (Group C). The animals were sacrificed by ether overdose at 31, 62 and 75 d of age (4-5 rats per group). Epididymis were dissected out and weighed. Left epididymis was fixed in 4% formaldehyde in PBS and right epididymis was finely minced and suspended in 2 % formaldehyde in PBS. Sperm counts were performed with Neubauer's hemacytometer and results expressed as spermatozoa /mg epididymis. Samples were processed for H&E stain and PAS and lectinhistochemical techniques. The following biotinylated lectins were employed: SBA, UEA, PNA, DBA, CON-A, RCA, and WGA. Results were expressed as mean±SEM and analyzed by Student's *t* test. Treated animals showed minor corporal and epididymal weights. Spermatozoa count outcomes from 62 and 75 d resulted lower group A animals with respect to control group. Variations in lectinhistochemical study were related to age and treatment. In regard to lectinhistochemical results the tubular content showed higher labelling in group C. Alloxan treatment could produce alterations in the sperm production and in the glucidic radicals pattern in the epididymis.

(45)

**MAST CELLS IN MICE INFECTED WITH *Tritrichomonas foetus*:
A QUANTITATIVE STUDY**

Woudwyk M^{1,4}; Monteavaro C²; Cacciato C²; Soto P²; Catalano V¹; Echevarría H²; Catena M²; Gimeno E^{3,4}; Barbeito CG^{1,3,4}.

1 Cátedra de Histología y Embriología, Facultad de Ciencias Veterinarias. Universidad Nacional de La Plata.

2 Laboratorio de Microbiología Clínica y Experimental, Universidad Nacional del Centro de la Provincia de Buenos Aires. Tandil, Argentina.

3 Instituto de Patología, Facultad de Ciencias Veterinarias. Universidad Nacional de La Plata. La Plata.

4 CONICET.

E-mail: marianawoudwyk02@hotmail.com

The bovine tritrichomonosis is a venereal disease due to the protozoan *Tritrichomonas foetus* that produces embryonic death and abortion. Mast cells granules contain vasoactive substances, that when released, affect vascular permeability. Besides, mast cells have a protective role in the mucosa and regulate the uterine contractibility. Some authors have shown that these cells' increase is associated with pregnancy loss. The aim of this work was to analyze the number and distribution of the mast cells in the uterus of mice infected with *Tritrichomonas foetus*. We used Balb/c mice with 5, 7, 8, 9 and 10 days of pregnancy, infected with the protozoan via intravaginal 10 days prior to the mating. Not infected animals in the same pregnancy days were used as control group. The uterine horns samples were processed for its coloration with H&E, Giemsa and toluidina's Blue. Ten microscopic fields under a 40X objective were observed and the average of mast cells per field was determined in the myometrium and the average \pm error standard of each group. The results were analysed with Student's *t* test. Mast cells were distributed in the myometrium and mesometrial triangle both in controls and infected mice. The largest concentration of mast cells was observed in the myometrium. In any case mast cells were observed in the decidua. Cells per field averages resulted similar in all groups. Preliminary results presented in this study do not support the hypothesis of an increase of mast cells in the infected animals, and their involvement in the pathogenesis of embryonic death.

(46)

**REINTERPRETATION OF TWO AFRICAN SPECIES OF THE GENUS
CHORDODES: *C. ibembensis* AND *C. uncinatus* (GORDIIDAE, NEMATOMORPHA)**Zanca F¹; De Villalobos C².¹ CONICET.² CIC. Facultad de Ciencias Naturales y Museo. Universidad Nacional de La Plata. La Plata, Argentina.E-mail: fmzanca@fcnym.unlp.edu.ar

The genus *Chordodes*, with 90 known species, is distributed mainly in tropical and subtropical zones. At the moment, an intense revision of this genus is being made because most of the species are insufficiently described or with few details. In this work the holotypes of *C. ibembensis* and *C. uncinatus* deposited in Africa Museum Tervuren, Belgium are studied. Additionally, the holotype of *C. clavatus* from the Museum für Naturkunde, Berlin, was analyzed. Cross sections of the midbody region were washed and dehydrated in increasing series of ethanol. Later, critical point was made. The obtained pieces were metallized, mounted and observed under scanning electron microscope. It was observed that the *C. ibembensis* and *C. uncinatus* holotypes displayed equal characteristics as much in form as in distribution of their 5 areolar types: simple, elevated, bulging, crowned and circumcluster areoles. These same characteristics were also observed in the *C. clavatus* holotype. Therefore, we considered *C. uncinatus* and *C. ibembensis* as non-valid and synonymous species of *C. Clavatus*.

(47)

**EXFOLIATIVE VAGINAL CYTOLOGY IN THE PLAIN VISCACHA
(*Lagostomus maximus maximus*): ITS USEFULNESS IN THE DIAGNOSIS OF
REPRODUCTIVE CHANGES**

Flamini MA^{1,2}; Barbeito CG^{1,2,3}; Portiansky EL^{2,3}.

1 Cátedra de Histología y Embriología.

2 Instituto de Patología. Facultad de Ciencias Veterinarias, Universidad Nacional de La Plata. La Plata, Argentina.

3. CONICET.

E-mail: aflamini@fcv.unlp.edu.ar

The vaginal smear is a simple method used to recognize the cyclical changes in the vaginal epithelium. In some species but not in others, smears can indicate with enough precision, the moment of the oestrous. To determine whether the viscacha might be considered as a female of the first group, experiments were designed in that direction. Thirty adult female viscachas were captured in their natural environment. Samples were taken before the sacrifice, by vaginal washes with saline. Papanicolau and Shorr stains were applied. The following cellular types were identified: basal, cyanophilic intermediate, cyanophilic superficial, eosinophilic superficial, eosinophilic cornificated, mucous, erythrocytes, and leukocytes. In agreement with the characteristics of the reproductive cycle of the viscacha, females were divided into four groups: anestro (A), follicular phase (FF), pregnant with multiple implantations (PM) and pregnant at term (PT). Group A females had a great amount of leukocytes and high proportion of basal cells. The FF group was characterized by the major percentage of eosinophilic superficial cells and few basal cells. The most prominent feature in the colpocytogram of the PM and PT females was the presence of a high percentage of mucous cells and a low proportion of cyanophil and basal cells. The high percentage of eosinophilic cells in the FF females would indicate the proximity of the oestrous phase in these animals. The high percentage of mucous cells present in the smears of pregnant females would be useful for a fast and easy diagnosis of pregnancy in this species.

(48)

**MORPHOLOGY AND INFRACILIATURE OF A NEW SPECIES WITHIN THE
GENUS *Deviata* (CILIOPHORA, STICHOTRICHIA)**

Küppers GC¹; Lopretto EC¹; Claps MC².

1 Cátedra Zoología Invertebrados I, Facultad de Ciencias Naturales y Museo, Universidad Nacional de La Plata. La Plata, Buenos Aires, Argentina.

2 Instituto de Limnología "Dr. R. A. Ringuelet" (CONICET-UNLP), Florencio Varela, Argentina.

E-mail: gkoppers@fcnym.unlp.edu.ar

Soil ciliates from Argentina and the rest of South America are almost unexplored. The aim of the present study was to describe the morphology of a new species within the genus *Deviata*, which was discovered in dry soil samples obtained during the drought of a temporary pond from Buenos Aires province. Ciliates were studied *in vivo* and by means of silver staining with protargol. *Deviata sp.* measures 112-154 $\mu\text{m} \times 21\text{-}28 \mu\text{m}$ *in vivo* and is vermiform in shape. The contractile vacuole is located in mid-body on the left margin. The cytoplasm is densely packed with refractive globules that confer a darkish coloration at low magnification. The macronucleus is moniliform and the number of micronuclei ranges from 1 to 3. The oral apparatus is composed of 14-18 adoral membranelles and paroral and endoral membranes, which do not intersect. Somatic ciliature is conformed by 4 frontal cirri, 1 buccal cirrus, 6 longitudinal and slightly spiralled rows of cirri, and 2 dorsal rows of dikinetids. Longitudinal rows of cirri extend up to the posterior end of the body, except for the first row located on the right of the oral apparatus, which ends equatorially. A pair of non-ciliated kinetosomes is located between this last row and the first left row of cirri. *Deviata sp.* differs from the other species within this genus by having a moniliform macronucleus and the presence of 2 dorsal rows of dikinetids, clearly representing a new species.

(49)

**LECTINHISTOCHEMISTRY IN INDUCED FOLLICULAR CYSTS
IN RAT OVARIES**

Salveti NR¹, Barbeito CG^{2,3}, Gimeno Ef², Ortega HH¹.

1 Laboratorio de Investigaciones Histológicas Aplicadas /Cátedra de Histología y Embriología, Universidad Nacional del Litoral. Esperanza, Argentina.

2 Instituto de Patología. Facultad de Ciencias Veterinarias. Universidad Nacional de la Plata. La Plata, Argentina.

3 Cátedra de Histología y Embriología, Facultad de Ciencias Veterinarias. Universidad Nacional de la Plata. La Plata, Argentina.

E-mail: salvetti@fcv.unl.edu.ar

The aim of this study was to detect changes in the lectinhistochemistry binding pattern in the wall of ovarian cysts. Wistar rats were housed in permanent light rooms along 90 days. A control group was housed in a standard lighting regimen; these animals were sacrificed in proestrus. Samples of the ovaries were processed for incubation with the following byotinated lectins: WGA, Con-A, DBA, SBA, PNA, RCA-1 and UEA-1. We analysed the granulosa of normal, atretic and cystic follicles; interstitial cells, zona pellucida, mesothelium and vessels, in both groups, and corpora lutea in the controls. We found loss of PNA and SBA binding in granulosa of the cysts in relation to the growing follicles. The PNA, SBA and WGA binding disappeared in the interstitial cells of the ovaries with cyst follicles. Residues of zona pellucida found in the atretic follicles of the cystic ovaries had not the Con-A affinity characteristic of the growing follicles. In the granulosa, the lectin affinity was minor in the atretic follicles. The staining in the endothelium was similar in both groups. In conclusion, there was a minor lectin binding, and consequently a minor expression of sacharides in the cystic ovaries. The sacharides lost could be: N acetyl-D galactosamine and D-galactose. These carbohydrates could be related with different physiological processes. The changes are added to other found in previous studies, namely modifications in growth factors and cytoskeleton proteins expression.

(50)

**THE TYPES OF THE SUBFAMILIES TYPHLOCYBINAЕ, DELTOCEPHALINAЕ,
CICADELLINAЕ AND GYPONINAЕ (HEMIPTERA: AUCHENORRHYNCHA:
CICADELLIDAE) HOUSED AT THE MUSEO DE LA PLATA, ARGENTINA**

Paradell S; Dellapé G; Catalano MI.

División Entomología. Facultad de Ciencias Naturales y Museo. Universidad Nacional de La Plata. La Plata, Argentina.

E- mail: paradell@fcnym.unlp.edu.ar; gimenadellape@hotmail.com; icatalano@fcnym.unlp.edu.ar

The family Cicadellidae includes approximately 22,000 species described in the world, assembled in 38 subfamilies of which 20 are present in the fauna of the Neotropic and eight in Argentina. These insects are exclusively phytophagous. They carry different pathogens that cause damage to cultivated and wild plants. The aim of this contribution is to make a report of the type specimens of the subfamilies Typhlocybinae, Deltocephalinae, Cicadellinae and Gyponinae housed in the collections of the División Entomología of the Museo de La Plata (MLP). 88 type species of the families Cicadellidae were examined and listed: seven Typhlocybinae, 35 Deltocephalinae, 16 Cicadellinae and 30 Gyponinae. In the specific identification exo and endosomatic characters were used. For each type specimens information about the specific name, bibliographical reference and type and precedence category is given. The entomological collections preserve the type specimens or of reference, indispensable tool for the identification of the species as well as a biodiversity evidence.

INDICE DE AUTORES			
	A		
Abal A	19	Catena M	44
Abilleira E	26-27-28	Cecho A	41
Achinelly MF	5	Cerezo M	8-9-10
Allegretti PE	42	Cesani MF	7
Alvarez A	33	Claps MC	47
Andrés Laube PF	34-37-40	Colaci P	22-30
Andrini LB	1-22	Corrons F	30
Anselmino C	19	Coscarelli L	8-9-10
Aquino DA	2	Costi D	38-39
Arcamone L	8-9-10	Criminaldi D	4-11
Arcuri M	3	Cuello M	12
Armendano A	4		D
	B	De Simone R	39
Barbeito CG	15-20-24-29- 34-37-40-43- 44-46-48	De Villalobos C	13-41-45
Basal R	32	Degrange FJ	14
Batista S	19	Del Viso S	3-18
Baudo J	41-42	Dellapé G	49
Braccini MC	16	Delocca M	26-27
Bruno M	3	Desántolo B	38
Buezas M	8-9-10	Di Salvi N	42
Bustamante C	26-27	Díaz MC	15
	C	Díaz AO	16-17
Cacciato C	44	Domínguez GE	41-42
Camino NB	5	Dorati P	18
Cantarini M	32	Durso G	4-19
Caserío J	28		E
Castagno L	28	Echevarría H	44
Castilla S	39	Errecalde AL	1-21-22-30-38
Castro L	7	Escalante AH	17
Catalano MI	49	Escudero Giachella E	31
Catalano V	44	Etchegoyen L	32
Catanesi CI	6		F
		Fernández Blanco A	21-22
		Fingermann G	26-27-28
		Flamini MA	46
		Forte LM	7
		Friso E	31

Furnus CC	22	Marini J	30
	G	Márquez SG	20-29
Galotta JM	20-29	Martín C	30
García AL	21-22	Martínez C	31
García AM	16-17	Mastrancioli M	4
García Gadda B	32	Mayocchi K	18
García Gadda G	32	Mazeo D	26-27
García Mancuso R	38	Medina JL	11
García MN	1-22	Mendes C	4
García Romero N	37	Méndez MG	6
García M	12-38	Mercado M	3
Gelfo JN	23	Micinquevich S	3-18
Gimeno EJ	40-44-48	Milat E	32
Goldemberg AL	17	Miquelini LA	39
Gómez S	15	Monteavaro C	44
González A	31	Morgan CC	33
González NV	24		N
Guimarães ACG	16	Najle R	15
Gullo BS	25	Nascimento EF	40
	H		O
Hisano N	43	Obiols C	4-31
	I	Olivares AI	33
Inda AM	1-22-38	Orden AB	7
Irigoyen S	26-27	Ortega HH	48
	K	Oviedo Arévalo J	31
Küppers GC	47	Oyhenart EE	7
	L		P
Laguens M	38	Pacheco Marino SG	34
Licata L	19	Paggi R	38
Lima FB	16	Paradell S	49
Luis MA	7	Penalva M	41
Lopretto EC	47	Perez Fre D	8-9
Luna ME	7	Picasso MBJ	35-36
	M	Pilone L	11
Maliandi N	38	Pinheiro Jr C	16
Mancuso P	26-27-28	Plaul SE	34-37
Margaría CB	2	Plischuk M	38

Portiansky EL	20-29-46		
Prat G	38-39		
	Q	Zanca F	13-41-45
Quintero FA	7	Zonta ML	7
	R		
Rasse N	4-11		
Rom M	3		
	S		
Salceda S	38		
Salibián A	34		
Salvatore M	3		
Salveti NR	48		
Sambartolomeo P	41		
Sant'Ana FJF	40		
Sarmiento P	41		
Schargarodsky G	5		
Schlain S	39		
Segatto R	26-27		
Sicre ML	7		
Silbestro M	6		
Solari A	12		
Somoza G	12		
Soto P	44		
	T		
Tambussi C	36		
Tanevitch A	19		
Torres MF	7		
Tosti S	41-42		
	V		
Vázquez SMV	43		
Verzi DH	33		
Vidal Rioja L	6		
Viscovick C	28		
	W		
Woudwyk M	44		

INSTRUCCIONES PARA LOS AUTORES

La revista Ciencias Morfológicas es el órgano oficial de la Sociedad de Ciencias Morfológicas de La Plata.

Trabajos

La revista de la Sociedad acepta los siguientes tipos de trabajo relacionados con el campo de las ciencias morfológicas en cualquiera de sus niveles:

Trabajos completos, que contengan nuevos datos científicos provenientes de investigaciones originales.

Comunicaciones breves sobre investigaciones en ejecución.

Resúmenes de trabajos comunicados en congresos de la disciplina, por acuerdo entre las autoridades del evento y el Comité de Política Editorial de la revista.

Actualizaciones y/o revisiones de temas de interés a solicitud del Comité de Política Editorial.

Reseñas de libros de la especialidad.

Cartas al Editor como medio de difusión de ideas y comentarios sobre artículos publicados con anterioridad.

Los trabajos completos podrán tener una extensión máxima de 15 páginas y podrán incluir hasta 25 citas bibliográficas.

Las comunicaciones cortas no deberán exceder las 3 páginas ni las 10 citas bibliográficas.

Las actualizaciones y/o revisiones no deberán exceder las 30 páginas incluidas las citas bibliográficas que no podrán ser más de 100.

Las reseñas de libros de la especialidad no deberán superar dos páginas.

Las cartas al editor no deberán superar las 1000 palabras.

Política editorial

Se someterán los trabajos presentados a la consideración de un jurado constituido por un mínimo de dos árbitros, miembros del Comité de Política Editorial o del Consejo Científico Editorial. La aceptación de los trabajos para su publicación, se resolverá sobre la base de las sugerencias del jurado.

Los editores se reservan el derecho de hacer correcciones gramaticales y de estilo y, en caso de ser necesario, devolver el manuscrito a los autores para su re-escritura.

El envío de un manuscrito al editor implica que no ha sido publicado previamente y que no se encuentra en evaluación para su publicación en otra revista.

Idioma

La revista acepta trabajos en idioma castellano o en idioma inglés. Se aceptarán trabajos en otros idiomas cuando así lo aconseje el Comité de Política Editorial.

Preparación de los manuscritos

Formato

Todos los trabajos serán escritos con procesador Microsoft Word, con extensión .rtf, en papel blanco tamaño A4 (210 x 297 mm), a doble espacio, simple faz y numerados. Los márgenes a emplear son 4 cm a la izquierda y no menor que 2 cm en el derecho. El texto deberá estar alineado a la izquierda y sin aplicación de sangrías, saltos de página o secciones.

No incluir encabezados, pies de página ni notas al pie.

La página inicial deberá contener:

- Título completo del trabajo. El título debe ser conciso e informativo en castellano y en inglés
- Título abreviado (castellano o inglés, según el idioma principal del trabajo), que no supere los 50 caracteres (incluyendo puntuación y espacios).
- Palabras clave: hasta 5 palabras (castellano e inglés).
- Apellidos y nombres completos de los autores
- Institución donde se desarrolló la investigación: nombre completo de la institución, incluyendo departamento y/o centro de investigación, ciudad, código postal y país.
- Otras filiaciones institucionales de los autores
- Nombre, dirección postal y electrónica, número telefónico y/o fax del autor a quien deba dirigirse la correspondencia.
- Un resumen de 200 palabras que indicará los aspectos nuevos, diferentes y significativos del trabajo, este deberá ser presentado en castellano y en inglés. No incluirá referencias bibliográficas ni abreviaturas.
- Número total de figuras, gráficos y tablas.

Organización del manuscrito

Los trabajos completos y comunicaciones cortas tendrán las siguientes secciones:

Introducción: se indicará la naturaleza y alcance del problema investigado, como también los objetivos y diseño de la investigación.

Materiales y métodos: descripción minuciosa y detallada del diseño experimental, métodos, procedimientos y aparatos empleados, con claridad suficiente para que los experimentos puedan ser reproducidos. También deberá hacerse mención a los procedimientos de valoración de los resultados y métodos estadísticos aplicados, incluyendo los programas informáticos.

Los animales, plantas y microorganismos experimentales deberán identificarse utilizando las designaciones de género, especie y cepa.

Resultados: se recomienda ajustarse a la descripción de los datos científicos, en forma breve y clara, incluso los resultados negativos. Deben mencionarse todas las tablas y figuras. Es aconsejable no repetir en el texto los datos de las tablas.

Discusión: deberá limitarse al análisis e interpretación de los resultados, su significado y relaciones con lo conocido y reseñado hasta el momento en la literatura. Se podrá agregar un párrafo de conclusiones.

Agradecimientos: sección destinada a la mención de colaboradores, asistentes técnicos, apoyo financiero, etc. que contribuyeron a la investigación.

Referencias: las citas bibliográficas en el texto se harán con números arábigos sucesivos, colocados entre paréntesis, que se corresponderán con la lista de referencia.

La lista de referencias deberá escribirse al final del manuscrito y cada cita deberá estar precedida por el número utilizado en el texto. La confección de la lista seguirá la siguiente forma:

Para citas de revistas

(número de cita) Autores separados por coma, año de publicación. Título del trabajo. Revista volumen: página inicial y final.

Ejemplo: McCoard SA, Wise TH, Ford JJ. (2003). Germ cell development in Meishan and White Composite gilts. *Anim Repr Sci*; 77:85-105.

Para citas de libros

(número de cita) Autores separados por coma. Año. Título del libro. Editorial, lugar y país.

Ejemplo: Kuby J. (2000) *Antigen-Antibody Interactions*. Immunology. WH Freeman and Co, New York, USA.

Para capítulos de libros

(número de cita) Autores separados por coma. Año. Título del capítulo. Título del libro, editores, autores o compiladores del libro, editorial, lugar y país, páginas inicial y final.

Ejemplo: Gardner RL, Papaianou VE. (1975) Differentiation in trophoectoderm and inner cell mass. En *The early development of Mammals*, Balls M. & Wild AE (eds) Cambridge University Press, Cambridge, New York, pp. 107-132.

Para comunicaciones en congresos, reuniones y conferencias

(número de la cita) Autores separados por coma. Año. Título de la presentación. Nombre del congreso, reunión o conferencia. Ciudad y fecha; editor(es). Lugar de publicación, número de comunicación, páginas inicial y final.

Ejemplo: Casciotta JR, Almirón AE. (1999) Adaptación morfológica de peces characiformes a ambientes acuáticos continentales con baja concentración de oxígeno disuelto. I Congreso Internacional de la Sociedad de Ciencias Morfológicas de La Plata. La Plata, junio 23-26. La Plata, comunicación N° 10, p. 16.

Para publicaciones electrónicas

(número de cita) Incluir el URL y la fecha de acceso en la cita [mes-día-año].

Ejemplo: Weber JE. (2002). Developing a Departmental Style Guide. [En línea] TECHWR-L, RayComm

<<http://www.techwr-.com/techwirl/magazine/writing/sytleguide.html>> [Consulta: 10-5-2004]

Preparación de tablas y gráficos

Las tablas y los gráficos serán numerados con números arábigos en el orden en que se mencionen en el texto. Cada tabla y/o gráfico debe acompañarse de una breve leyenda. Si se emplearan abreviaturas, deberán ser aclaradas al pie de la tabla y/o gráfico o ser incorporadas en el texto.

Se recomienda el uso de Microsoft Word o Excel para la confección de las tablas y gráficos.

Se presentarán en hojas separadas, al final del manuscrito. En el texto se señalará la posición correspondiente con la indicación “insertar tabla / gráfico N°...”.

Ilustraciones

Las ilustraciones se mencionarán en el texto como “fig”, numeradas con números arábigos. Solo se aceptarán dibujos y fotografías de excelente calidad, los cuales deberán ser digitalizados e incluidos en archivos separados.

Se presentarán en hojas separadas, al final del manuscrito. En el texto se señalará la posición correspondiente con la indicación “insertar fig. N°.....”.

No deben enviarse originales, negativos ni fotocopias.

Las medidas de las ilustraciones no deben exceder los 11,5 cm (ancho) x 15 cm (alto) y deberán dejar espacio al pie para la leyenda.

Cuando los autores tengan necesidad o interés en incluir ilustraciones en color, el costo de las mismas serán asumido por los interesados.

En el caso de las actualizaciones y/o revisiones, la distribución de secciones queda a criterio del autor en tanto faciliten la comprensión del tema. Se requiere la presentación de un resumen cuya extensión máxima será de 300 palabras. Las referencias se citarán como se indica más arriba.

Las cartas al Editor y las reseñas de libros tendrán una organización del texto que debe seguir las pautas generales para una exposición clara y fundamentada de los conceptos y opiniones vertidas.

Envío de los manuscritos

Por cada contribución se enviará:

Por correo postal: una copia en diskette o CD y dos copias en papel.

Dr. Claudio Barbeito. Cátedra de Patología General Veterinaria. FCV - UNLP. 60 y 118 s/n

Por correo electrónico: al Editor Científico exclusivamente (barbeito@fcv.unlp.edu.ar)

Los autores deben guardar una copia de todos los materiales enviados, inclusive fotografías, ya que no se aceptará responsabilidad por daño o extravío de los mismos.