

# A MAN FROM SAN JUAN: FACIAL APPROXIMATION WITHIN ANTHROPOLOGY

Susan Hayes

*School of Anatomy and Human Biology, Faculty of Life and Physical Sciences, University of Western Australia, Australia*

**KEY WORDS** facial reconstruction; Huarpe; cranial remains

**ABSTRACT** Within both anthropology and forensic identification, a facial approximation (also known as “facial reconstruction”) is often presented as an accomplished fact, with minimal, or no evidence of the research and methods used to achieve the result. This paper presents a detailed overview of the research and methods used for a 2D computer graphic facial approximation of a prehistoric man unearthed in the Jachal Valley, San Juan Province, Argentina. Understood to be a member of the extinct Huarpe, this individual’s skull displays many of

the morphological features that are consistent with what is known about this group of early Amerindian farmers. Because many of the recommended methods that inform this facial approximation have yet to be verified, and those that have been appropriately tested are based on statistical averages of human variation, the results need to be viewed as indicative of this individual’s possible facial appearance using current levels of knowledge, rather than as a definitive result. *Rev Arg Antrop Biol* 13(1):71-81, 2011.

**PALABRAS CLAVE** reconstrucción facial; Huarpe; restos craneanos

**RESUMEN** Dentro de la antropología y la identificación forense, la aproximación facial (también conocida como “reconstrucción facial”) se presenta frecuentemente como un hecho consumado, con evidencia mínima de las investigaciones y los métodos usados para alcanzar los resultados. Este trabajo presenta un panorama detallado de la investigación y los métodos usados para realizar una aproximación facial gráfica en 2D de un hombre prehistórico del valle de Jachal, provincia de San Juan, Argentina. Se entiende que corresponde a un miembro del extinto grupo Huarpe. El cráneo del individuo mues-

tra numerosos rasgos morfológicos que son consistentes con lo que se conoce acerca de este grupo de agricultores tempranos americanos. Debido a que muchos de los métodos utilizados en esta reconstrucción facial aun no han sido verificados y aquellos que han sido debidamente probados se basan en promedios estadísticos de la variación humana, los resultados presentados deben ser vistos como indicativos de la posible apariencia facial del individuo dado el nivel actual de conocimiento, más que como un resultado definitivo. *Rev Arg Antrop Biol* 13(1):71-81, 2011.

This paper presents a facial approximation of the remains of a pre-historic individual unearthed from the area of Jachal located in the north of the San Juan Province, Argentina. The method used is a combination of the 2D facial approximation method with computer graphic manipulation and digital drawing, and the face is built up in reference to both the soft tissue depth guidelines and underlying anatomical structures. Most of the analyses, together with the approximation of the underlying anatomy and the basic facial appearance, were accomplished in direct reference to the skull (E1807) which is part of the collections housed in the Museo de La Plata, Argentina. The structure of this paper is: firstly an overview of the main

methods, and issues, used in a facial approximation, followed by a brief summary of what is currently known about pre-historic individuals from the San Juan province, and where relevant, how these understandings are related to aspects of skull morphology. The remainder of the paper describes the facial approximation methods employed and the results ascertained for this individual.

---

Corresponding: Susan Hayes. School of Anatomy and Human Biology. M309 Faculty of Life and Physical Sciences. University of Western Australia. Stirling Highway. Crawley 6009 Australia. E-mail: susan.hayes@uwa.edu.au

Recibido 13 Abril 2011; aceptado 23 Junio 2011

### Facial approximation

The aim of a facial approximation of modern humans (also known as “facial reconstruction”) is to produce a reasonable likeness of a deceased individual based on what is known about the skull and how it relates to the surface appearance of the head and face. Within the field of forensic anthropology this likeness is disseminated across the mass media to stimulate leads to possible identity (Clement and Ranson, 1998), and typically occurs as a “last resort” when all other means to identify the deceased have failed (Snow et al., 1970). Within anthropology a facial approximation is occasionally produced to suggest the identity of an individual when the result can be compared to pre-existing images of the deceased, such as an authenticated portrait painting or sculpture (*e.g.* Kustar, 2004; Tiesler et al., 2004; Benazzi et al., 2009, 2010). Other applications within anthropology are to explore the effect of a particular aspect of bone morphology on facial appearance, such as artificial, medical or pathological craniofacial deformation (*e.g.* Kustar, 1999; Wilkinson and Neave, 2003; Gaytan et al., 2009), and/or an exploration of the facial appearance of an individual belonging to a particular socio-historical group or population that pre-dates artistic or photographic depiction (*e.g.* Prag and Neave, 1997; Cesarani et al., 2004; Hayes et al., 2009, 2011).

The methods used to produce a facial approximation vary, as do the materials. Broadly speaking, the main methods of facial approximation fall into two categories: building up relevant facial muscles and surface anatomy while referring to the soft tissue depth guidelines (*e.g.* Gerasimov, 1955, 1971; Prag and Neave, 1997; Wilkinson, 2004) or blocking in the face predominantly in reference to soft tissue depths alone (*e.g.* Snow et al., 1970; Helmer et al., 1993; Taylor, 2001). Traditionally, the materials used in a facial approximation are either 3D (clay, wax or plasticine over a cast of the skull) or 2D (drawing on vellum over photographic prints). It is recommended,

however, that all 3D facial approximations are performed in reference to a 2D result, as 3D modelling materials are not easily checked for the accuracy of the rendering (George, 1987). A more recent development is virtual facial approximation, incorporating differing levels of automation (for a review, see Claes et al., 2010), but even highly automated computer generated facial approximations still require some degree of expertise in digital drawing to complete the surface appearance of the deceased’s head and face. Possibly because undertaking a facial approximation requires knowledge of facial anatomy and human facial variation, together with some competence with the techniques of artistic depiction, the results can vary.

Related to issues of quality is the information used to inform a facial approximation. A major figure in the field is Mikhail Gerasimov (1955, 1971), who, like many anthropologists before him, based most of his skull-soft tissue recommendations on extensive experience rather than statistical evidence. Some of these recommendations, however, have been verified over the past few years, particularly in the area of approximating the shape of the mouth and nose (Wilkinson et al., 2003; Rynn et al., 2010). Not all practitioners refer to Gerasimov’s methodology, and there are a number of published facial approximation guidelines that are sourced directly from artistic canons. Artistic canons, however, were devised to produce an aesthetically idealised face (Gombrich, 1982; Bedaux, 1996), and are not a record of the actual means of human facial variation. Leslie Farkas has demonstrated the low statistical incidence of nearly all artistic canons being present in the adult head and face (Farkas and Munro, 1987; Farkas, 1994), while Carl Stephan has critically evaluated the validity of many of the more popular facial approximation guidelines and replaced some of these with recommendations that have an appropriate statistical reliability (*e.g.* Stephan, 2002, 2003; Stephan et al., 2003).

The facial approximation method described here locates the traditional 2D facial

approximation techniques fully within a computer graphic environment, and includes the use of layers, digital drawing and warping. Where possible only appropriately verified recommendations and methods have been used, but of necessity there is still reference to published recommendations that are as yet of unknown validity. This is particularly the case with Gerasimov (1955, 1971), Fedosyutkin and Nainys (1993), and some of the recommendations and research cited within Prag and Neave (1997), Taylor (2001) and Wilkinson (2004).

### Prehistoric people of San Juan

The Jachal Valley is located in the North-West of the San Juan province, between the Andes and the plains. At least two related prehistoric Amerindian groups are reported as having inhabited the area, the Huarpes and the Diaguitas, with the Diaguita being located further to the north of the province (Chamberlain, 1912; Steward, 1946). Both groups are generally thought to have been farming communities, and by 1500BP farming had become the primary activity. Small villages were established in the river valley and irrigation systems developed to water crops, which included potatoes, beans and maize (Sardi et al., 2006). Farming, however, is thought to have been supplemented by hunting and fishing, and the seasonal gathering of wild plant foods (Canals Frau, 1946; Sardi et al., 2006). According to Canals Frau (1946) there is little archaeological evidence of the indigenous Huarpes, as the European colonists took over the same areas of land and in the process destroyed many indigenous burial grounds. However, there is some evidence that these farmers wove cloth, produced ceramic artefacts, and used mortars and pestles to grind their grain (Canals Frau, 1946; Sardi et al., 2006). There is reported evidence that the Huarpes differed in their overall appearance from their neighbours. Fabra et al. (2007) report that the Huarpes were tall individuals, with dark skin and dolichocephalic heads, which is in contrast to the more typi-

cal Andean morphology of shorter stature and brachycephalic head forms. This difference is also noted by Canals Frau (1946), who cites Father Reginaldo de Lizarraga (1589) as describing the Huarpes as “badly proportioned” and “gaunt”. By the early 1700s the Huarpes were extinct (de Lizarraga, 1589, cited in Canals Frau, 1946).

The Museo de La Plata collection of remains from the San Juan province, and in particular those from the Jachal Valley, are understood to be Huarpe from the late Agriculturalist period (500-800BP) (Perez, 2006; Sardi et al., 2006; Gonzalez et al., 2010). The group as a whole practised both occipital and fronto-occipital cranial deformation, although not all individuals display these patterns of compression (Sardi et al., 2006), and cranial remains found further to the north tend to display a slight to intermediate fronto-occipital and lambda compression morphology (Perez, 2006; Del Papa and Perez, 2007). Not all patterns of cranial compression are thought to be intentional, and in particular the tabular erect deformation pattern, which describes a slight compression in the occipital and lambdoid region of the cranium (Gonzalez et al., 2010), is thought to be due to the use of cradle boards to transport infants.

Compared to the hunter-gatherers to the south, the Huarpe farmers have been found to display larger nasal apertures, smaller masticatory muscle attachment patterns, and overall have smaller crania (Sardi et al., 2006). This tendency for lower absolute masticatory sizes of the farmer groups in the north-west compared to the southern hunter-gatherer groups has also been noted by González-José et al. (2005). There is a suggestion that the smaller masticatory sizes and indices for the farmers is an outcome of their agriculturalist diet. Compared to the hunter-gatherer populations, farmers from the north-west have also been found to display lower tooth wear rates and a greater number of caries. Bernal et al. (2007) suggest that the possible use of ceramic utensils to cook food, which softens the diet, would reduce overall patterns of tooth wear,

and maize is understood to be a highly cariogenic food source. However, although farmer populations have been found to display lower rates of tooth wear than the hunter-gatherers, the teeth of agriculturalists still display wear patterns, as pre-historic farmers would likely have incorporated grit into their food preparation (Bernal et al., 2007). Canals Frau (1946) reports archaeological findings of mortars in Huarpe archaeological sites in Mendoza, and if these were used to grind edible grains in Jachal, then grit from the mortars would have entered the diet. Further, the Huarpe are understood to have been seasonal agriculturalists (Canals Frau, 1946), incorporating hunting and fishing and wild plant foods into their diet—all of which have also been related to causing tooth wear (Sardi et al., 2006).

In the area of overall craniofacial shape the hunter-gatherers and the farmers have been found to not clearly differentiate (González-José et al., 2005). In addition, both groups display a marked robusticity in their skull morphology, and while there is some increase in robusticity that parallels an increase in latitude, Bernal et al. (2006) have not identified a significant relationship between differences in diet and overall rugosity. Further, the robusticity patterns which differentiate the farmer and hunter-gatherer groups has been found to be present from approximately 5 years of age, and that the sub-adult traits of robusticity are similar to those of adults from the same geographic region (Gonzalez et al., 2010). There is a general feeling that, rather than adaptive or selective pressures, the differences in the cranial morphology of the farmer and hunter-gatherer populations are likely due to disruptions in the history and structure of the different groups (González-José et al., 2005), and there are suggestions that the North-West populations of South America are the result of separate colonisation patterns from those of the Central and Southern areas of South America (Fabra et al., 2007). For a recent detailed study of the skeletal attributes of pre-historic hunter gatherer and farmer populations from the Centre-West of South America, see Sardi

and Béguelin (2010).

### Facial approximation of E1807

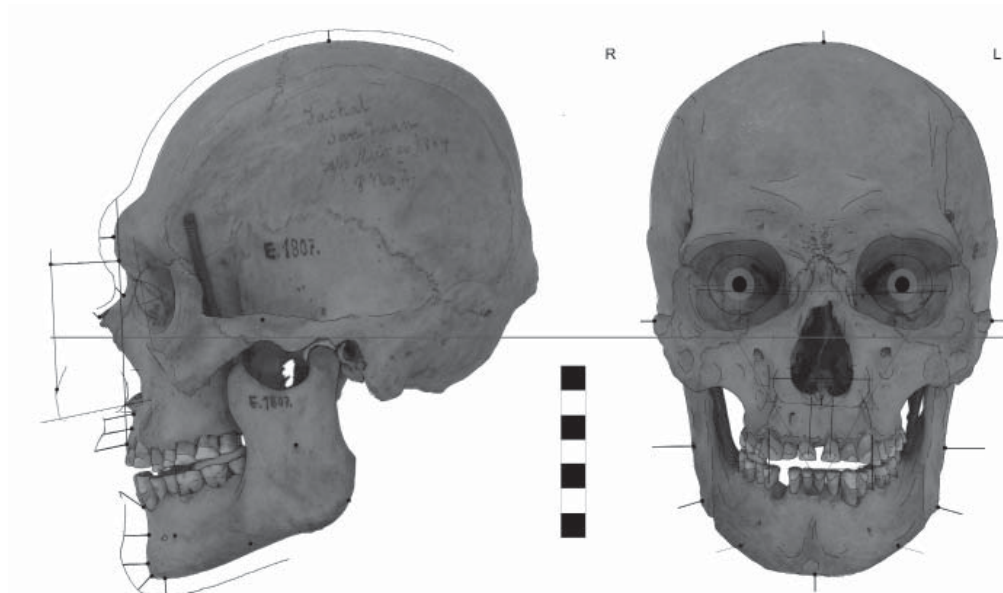
This individual was unearthed from the Jachal area, San Juan Province, with both cranial and post-cranial remains. Overall the cranium and mandible are large, rugose, and in a good state of preservation (*e.g.* the bones are undamaged, the anterior nasal spine is intact, and there is minimal post-mortem tooth loss). There is some indication of the tabular erect deformation pattern (Gonzalez et al. 2010), the third molars are present, and the teeth are well worn.

### General morphological and anthropometric considerations

Anthropometric measures and visual assessments indicate that this individual has a slightly pentagonoid cranial shape and brachycephalic head form (Cranial Index 82.3), though the cranial index could be influenced to some extent by the presence of compression in the lambdoid region. The mandible displays a wide and somewhat low right coronoid process and a gonial angle of  $105.6^\circ$ , which is less than  $125^\circ$  and this is understood to be consistent with a rounded or rectangular face shape (Fedosyutkin and Nainys, 1993). The zygomatic vertical profile ( $52.8^\circ$ ) is neither acutely angled or relatively flat, and this profile does not fit within the population ranges observed by Gerasimov (less than  $50^\circ$  is more typically associated with Europeans while angles greater than  $65^\circ$  is typically associated with Asian populations) (Gerasimov, 1955). The results of these considerations are shown in Figura 1.

### Sex and age determination

This individual displays a marked level of rugosity, and in particular displays a prominent brow ridge and marked muscle attachments on the upper facial bones. Ascertaining sex of a rugose skull is made difficult as many of the craniofacial measures and assessments



**Fig. 1.** E1807 Anthropometrics, soft tissue depths, feature location and size.

used to ascertain sex are similar to those used to determine rugosity (Bernal et al., 2006). Because this individual was unearthed with post-cranial remains, sex estimation was able to be ascertained using both pelvic and cranial features (Gonzalez, 2008). Sex estimation of the pelvic structures used four morphological traits following Phenice (1969) and Buikstra and Ubelaker (1994): ventral arch on the ventral surface of the pubis; subpubic concavity; medial aspect of the ischio-pubic ramus; and greater sciatic notch. The traits scored in the skull were glabella, supraorbital margin, mastoid process, arcus superciliaris, crista supra-mastoidea, and overall aspect of mandible (Buikstra and Ubelaker, 1994; Graw, 2001). On the basis of these features the skeleton E1807 was determined to be most likely male (Gonzalez, 2008).

An analysis of the pubic symphysis and the auricular surface of the ilium (Buikstra and Ubelaker, 1994), indicated that this individual was a mid-aged adult (35-50 years old) at the time of death (Paula Gonzalez, personal communication). Age estimation is also suggested by tooth eruption and the pattern of tooth wear. With this individual the teeth

are worn, with the central incisors displaying approximately 4mm of enamel. As noted by Deter (2009), tooth wear patterns are related to the order of tooth eruption as well as dietary factors. In this individual the third molars are present, and display a similar wear pattern as the first and second molars. This suggests the eruption of the third molars was not recent at the time of death, and therefore the individual was likely to have been a mid-aged adult.

#### **Articulation of the mandible and 2D image acquisition**

The mandible was articulated to best fit with the dental occlusion and positioned with a 2mm spacer between the condylar process and the mandibular fossa simulating the articular disc, and a further spacer was placed between the molars (Prag and Neave, 1997; Taylor, 2001). The skull was orientated to the Frankfurt Horizontal Plane, and digitally photographed in both the frontal and lateral views. The camera used was a Panasonic Lumix DMC-ZR1 (Leica lens), set to normal picture mode with the flash disabled, and mounted on a tripod from a distance of 2 meters from the



skull to ensure orthogonal images (*e.g.* no barrel distortion). The frontal images were centred on the nasion using the grid LCD display, with the lateral images centred to a point midway between the nasion and the inion. These images were uploaded into Adobe Photoshop CS2, and scaled according to the maximum nasal aperture width in the frontal view, and the inter-landmark distance nasion-subspinale for the lateral view. Frontal and lateral articulation of the mandible, together with the results of the metric and morphological calculations undertaken (and described earlier) can be seen in Figure 1.

### Soft tissue depths

Rather than using soft tissue depths derived from a specific extant population group (*e.g.* European), the soft tissue depths, and their angle relative to the bone surface, were taken from the weighted means calculated by Stephan and Simpson (2008). Stephan and Simpson (2008) have pooled a large number of robust soft tissue datasets, and their weighted means have broad applicability across populations. The soft tissue landmarks and their corresponding depths are shown in Table 1. This is a sub-section of the total soft tissue landmarks provided by Stephan and Simpson (2008), in that they are only those on the sagittal plane in the lateral view, and the coronal plane, together with the vertex and menton, in the frontal view.

### Approximation of the facial features

According to the orbital measures provided by Gerasimov (1955), this individual displays a rounded eye form (the width of the orbits are slightly greater than the height), with a middle type orbital profile (the eyeball sits comparatively centrally within the orbit). The orbital cavity displays a slight narrowing at the orbital rims, which can be associated with deep set, non-protrusive eyes. The superior and inferior orbital margins are thick, rounded and relatively dull, which suggests the eyelids

TABLE 1. *Soft tissue depths applied in the approximations*

Median points	Total Weighted Mean (mm)	SD+1	SD-1
<i>Lateral view</i>			
vertex	5,0	6,0	4,0
glabella	5,5	6,5	4,5
nasion	6,5	7,5	4,5
midnasal	4,0	5,0	3,0
rhinion	3,0	4,0	2,0
subnasale	13	15,5	9,5
midphiltrum	11,5	13,5	8,5
prosthion	11,5	14,5	8,5
lower lip	13,0	15,5	10,5
labiomentale	11,0	13,0	9,0
pogonion	11,5	13,5	8,5
gnathion	8,5	11,5	5,5
menton	7,0	9,5	4,5
<i>Frontal view</i>			
zygomatic	6,0	7,0	5,0
mid-ramus	17,5	21,5	13,5
gonion	10,0	16,0	4,0

Source: Stephan and Simpson (2008).

were comparatively thick. To estimate eyeball projection in the left lateral view, a line was drawn connecting the superior and inferior orbital rim, and the eyeball positioned allowing for a 3-4mm bulge of the cornea beyond that line (Stephan, 2002). The malar tubercle is slightly visible on the lateral margin of both orbits, and connecting these points to the lacrimal fossa suggests the approximate location of the orbital fissure (eye slit) (Gerasimov 1955; Fedosyutkin and Nainys, 1993). Eyeball diameter was taken to be the male average of 24.6mm (Wolff, 1997, cited in Wilkinson, 2004), the iris diameter 10-12mm, and the eyeball was located within the average distances of orbital rim at the malar tubercle to exocanthion (5mm) and the length of the medial canthus to the lacrimal fossa (5mm) (Larrabee and Makielski, 1993). Because this individual has a marked browridge, and the presence of thickening on the lateral edge of the superior orbital rim, this may suggest that the eyebrows were located low on the face, giving the impression of “overhanging eyebrows”, with a lateral triangular peak (Fedosyutkin and

Nainys, 1993).

The algorithms developed by Rynn et al. (2010) for estimating lateral nasal projection for all populations was used, together with their recommendations for approximating nasal tip and wing shape. Because this algorithm does not necessarily indicate the inferior border of the nasal tip, Rynn et al. (2010) recommend incorporating Gerasimov's (1955, 1971) method for locating the nasal tip (the intersection of a line continuous with the direction indicated by the anterior nasal bones with a line continuous with the direction indicated by the anterior nasal spine). Gerasimov (1955) also recommends that, on average, the top of the nasal wing starts where the crista conchalis meets the anterior rim of the nasal aperture, finishes approximately 4mm below the nasal base, and is at its deepest 6mm from the lateral edge of the aperture—all of which have been verified by Rynn et al. (2010). Gerasimov (1955) also suggests that the overall shape of the wing may be similar to the shape of the lateral lower border of the aperture. In addition, Rynn et al. (2010) have found that the profile of the nasal tip is significantly related to the angularity of the profile of the aperture, and provide support for Gerasimov's (1955) recommendation that any deviation of the vomer in the frontal view will indicate asymmetry in the shape of the soft nose. For this individual the vomer has an inverted "S" shape, with the upper right nose dominating and the lower left nose being wider at the base. The nasal base displays a slight "nasal wryness" (Woo, 1931), being slightly higher on the right than the left, which may be visible in the frontal view (Fedosyutkin and Nainys, 1993). The depth of the canine fossa (left 6mm, right 5mm) suggests this individual also displayed moderate nasolabial folds (Fedosyutkin and Nainys, 1993).

Because of the extent of tooth wear, the location of the oral fissure was difficult to ascertain as it is typically taken to be two-thirds to three-quarters of the height of the upper central incisors (Gerasimov, 1955; Wilkinson et al., 2003). Mouth width was approximated as corresponding to the canine-premolar junction

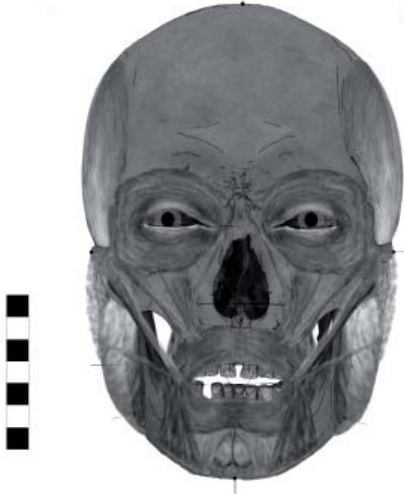(Wilkinson et al., 2003) which is approximately in line with the medial edge of the iris (Stephan, 2003). Lip height can be estimated with reference to the maximum height of the upper and lower enamel of the central incisors (Wilkinson et al., 2003), but with this individual this was not possible due to the extent of tooth wear. Instead, lower lip height was approximated using the Facial Triangle pattern (George, 1993, 2007), where the centre of the lower lip is estimated by drawing an equilateral triangle: exocanthion-exocanthion, right exocanthion-lower lip, left exocanthion-lower lip. Maximum upper lip (vermillion) height was taken to be approximately in the region of a point just below the prosthion. Upper and lower lip shape has been found to be influenced by the prominence of the upper and lower canines (Wilkinson et al., 2003), and this individual displays fairly prominent canines on both the maxilla and mandible. Therefore it is possible that this individual had a relatively full, flat upper lip and some lateral fullness to the lower lip.

The mandible does not overtly display gonial flaring, and there is a vertical groove on the mental eminence, indicating the possible appearance of a cleft in the chin (Gerasimov, 1971). The mastoid processes have a general, but not marked, downwards and inwards direction (relative to the FHP), suggesting the ear lobes were attached (Fedosyutkin and Nainys, 1993) and the pinna were not overly protrusive (Gerasimov, 1955). Ear height was taken to be similar to the distance between the soft tissue landmarks subnasale to menton (Farkas, 1987).

### Anatomical layers

The muscles and the parotid gland were built up in accordance with the descriptions provided by the 35th (Warwick and Williams, 1973) and 40th (Standring, 2008) editions of Gray's Anatomy. Each muscle and the parotid gland was shaped individually within a separate file using Adobe Photoshop CS2, and the muscles were warped onto the appropriate

bony attachments, with these attachment points having been approximated in reference to the skull itself. The warp mode was introduced in Adobe Photoshop CS2, and involves being able to apply a mesh over an image, or part of an image, and alter the dimensions either using handle manipulations along the mesh gridlines (similar to the handles used in vector graphics), or in a specific area of the image located within the mesh.



**Fig. 2.** E1807 Approximate anatomical build-up.

The muscles were built up from deep to superficial (Prag and Neave, 1997; Taylor and Angel, 1998; Needham, 2002; Wilkinson, 2004), and while this individual's skull displays marked muscle attachments, the decision was made to not exaggerate the size of these muscles. The surface appearance of the lips was not included with the orbicularis oris as this is better shaped as a surface feature, nor were the platysma, corrugators, nasalis, procerus or frontalis muscles approximated. Including the corrugators can add aspects of facial expression, which cannot be determined from the skull. Neither the nasalis nor the procerus have been found to have an impact on nasal morphology (Macho, 1989) and the cranial vault is typically recorded as having a fairly uniform soft tissue depth of approximately 5mm and closely follows the shape of the bone (Gerasimov, 1955). The nasal bridge


and upper forehead are therefore displayed by the morphology of the nasal and frontal bones. The full anatomical layer is illustrated in Figure 2.

### Surface appearance

The surface appearance was built up within the soft tissue guidelines (refer Table 1) and in reference to 60 images of indigenous South American male individuals displaying one or more of the approximate facial feature shapes as indicated by the analysis. The surface appearance was achieved using the digital drawing, warping and blending functions available in Adobe Photoshop CS2. Digital drawing involves using a graphics tablet and stylus (in this instance a Wacom Intuos 3, 9x12) to draw onto an image using the Photoshop brush and pencil settings. The warp function of Adobe Photoshop CS2 has been discussed previously (see Anatomical Layers), and the blending functions include being able to smudge and blur the boundaries between image segments, and use the dodge and burn tools to lighten and darken selected areas.

There is some suggestion that the prehistoric Huarpe had long dark hair (Canals Frau, 1946), but because hair type, colour and style cannot be ascertained from the skull, and that hair style has been found to have a significant impact on the overall appearance of the face (Shepherd et al., 1981; Bruce and Young, 1998) the presence of hair is minimally indicated for this individual by using shading which closely follows the shape of the cranial arc. There was no effort to inscribe age on the face or its features, other than that of general adulthood, as mid-adulthood spans a considerable period (35-50 years) and the adult aging process of face is reported to be highly variable, both within and between populations (Gerasimov, 1955). There is some visibility of the underlying bone and approximated musculature, both to reduce the amount of extraneous information being imposed on the skull and to clearly indicate this is an approximate facial appearance achieved predominantly through anthropological methods. Once the overall





**Fig. 3.** E1807 approximate surface appearance.

face and neck had been blocked in, the image was further rendered using the Adobe Photoshop CS2 “soft grain” filter tool (which adds speckles of “noise” to the pixel composition of the image) to better resemble the approximate nature of a sketch (see Fig. 3).

### SUMMARY

This paper presents the methods and results involved in a 2D computer graphic facial approximation of a pre-historic Amerindian skull unearthed from the Jachal Valley, located in the north of San Juan Province, Argentina. Understood to be the remains of an individual from the now extinct Huarpe, this man displays many of the robust morphological features associated with this group, and while the cranial index suggests a brachycephalic rather than dolicocephalic head form, this could be due to the presence of compression in the lambdoid region. Tooth wear patterns are consistent with this individual belonging to a Huarpe farming community, though the extent of the wear makes the formation of the lips highly speculative. Related to this point, and as suggested, not all of the published recommendations that have informed this method

of facial approximation have received verification by modern scientific standards. However, even where skull-soft tissue relationships have been appropriately verified (*e.g.* Macho, 1989; George, 1993; Stephan, 2002; Stephan et al., 2003; Wilkinson et al., 2003; Stephan and Simpson, 2008; Rynn et al., 2010), these findings are still only statistical averages of human variation. Therefore, although the use of the grain filter tool in Adobe CS2 results in a fuzzy image, this is preferable to a facial approximation that is highly photographic in appearance, as this could imply a greater level of precision in the process than is ever likely to be possible.

### ACKNOWLEDGEMENTS

Sincere gratitude to Héctor M. Pucciarelli, Jefe División Antropología, Facultad de Ciencias Naturales y Museo de La Plata (UNLP), for granting access to the material and resources, and enabling this project to be undertaken. In particular thanks to Mariano Del Papa, Marien Béguelin, Paula Gonzalez, Marina Sardi and Héctor Pucciarelli for their encouragement and generosity, and in making me so very welcome. Thanks also to Nick Milne, University of Western Australia, and Sergio Vizcaino, Division Paleontología Vertebrados, Museo de La Plata (UNLP), for their help in facilitating my visit to the Museo de La Plata in 2010.

### LITERATURE CITED

- Bedaux JB. 1996. From normal to supranormal. Observations on realism and idealism from a biological perspective. In: Woodfield R, editor. *Gombrich on Art and Psychology*. Manchester: Manchester University Press. p 171-195.
- Benazzi S, Bertelli P, Lippi B, Bedini E, Caudana R, Gruppioni G, Mallegni F. 2010. Virtual anthropology and forensic arts: the facial reconstruction of Ferrante Gonzaga. *Journal of Archaeological Science* 37(7):1572-1578.
- Benazzi S, Fantini M, De Crescenzo F, Mallegni G, Mallegni F, Persiani F, Gruppioni G. 2009. The face of the poet Dante Alighieri reconstructed by virtual modelling and forensic anthropology techniques. *Journal of Archaeological Science* 36:278-283.

- Bernal V, Novellino P, Gonzalez P, Perez SI. 2007. Role of wild plant foods among late Holocene hunter-gatherers from Central and North Patagonia (South America): An approach from dental evidence. *American Journal of Physical Anthropology* 133:1047-1059.
- Bernal V, Perez SI, Gonzalez P. 2006. Variation and causal factors of craniofacial robusticity in Patagonian hunter-gatherers from the Late Holocene. *American Journal of Human Biology* 18:748-765.
- Bruce V, Young A. 1998. *In the eye of the beholder: The science of face perception*. Oxford: Oxford University Press.
- Buikstra JE, Ubelaker DH. 1994. Standards for data collection from human skeletal remains. Proceedings of a seminar at the Field Museum of Natural History. Fayetteville, Arkansas: Arkansas Archeological Survey.
- Canals Frau S. 1946. The Huarpe. In: Steward JH, editor. *Handbook of South American Indians: The Marginal Tribes (Volume 1)*. Washington: Smithsonian Institution Bureau of American Ethnology Bulletin 143. p 169-175.
- Cesarani F, Martina MC, Grilletto R, Boano R, Roveri AMD, Capusotto V, Giuliano A, Celia M, Gandini G. 2004. Facial reconstruction of a wrapped Egyptian Mummy using MDCT. *American Journal of Roentgenology* 183(3):755-758.
- Chamberlain AF. 1912. The Allentiacan, Bororoan, and Calchaquian linguistic stocks of South America. *American Anthropologist* 14(3):499-507.
- Claes P, Vandermeulen D, De Greef S, Willems G, Clement J, Suetens P. 2010. Computerized craniofacial reconstruction: conceptual framework and review. *Forensic Science International* 201:138-145.
- Clement JG, Ranson DL. 1998. Craniofacial identification. In: Clement JG, Ranson DL, editors. *Craniofacial identification in forensic medicine*. London: Arnold. p 3-8.
- Del Papa MC, Perez SI. 2007. The influence of artificial cranial vault deformation on the expression of cranial nonmetric traits: Its importance in the study of evolutionary relationships. *American Journal of Physical Anthropology* 134(2):251-262.
- Deter CA. 2009. Gradients of occlusal wear in hunter-gatherers and agriculturalists. *American Journal of Physical Anthropology* 138:247-254.
- Fabra M, Laguens A, Demarchi D. 2007. Human colonization of the Central Territory of Argentina: Design matrix models and craniometric evidence. *American Journal of Physical Anthropology* 133:1060-1066.
- Farkas LG. 1987. Age- and sex-related changes in facial proportions. In: Farkas LG, Munro IR, editors. *Anthropometric facial proportions in medicine*. Springfield: Charles C Thomas. p 29-56.
- Farkas LG. 1994. *Anthropometry of the head and face*. New York: Raven.
- Farkas LG, Munro IR. 1987. *Anthropometric facial proportions in medicine*. Springfield: Charles C Thomas.
- Fedosyutkin B, Nainys J. 1993. The relationship of skull morphology to facial features. In: Iscan MY, Helmer RP, editors. *Forensic analysis of the skull: craniofacial analysis, reconstruction, and identification*. New York: Wiley-Liss. p 119-213.
- Gaytan E, Mansilla-Lory J, Leboreiro I, Pineda S. 2009. Facial reconstruction of a pathological case. *Journal of Forensic Science, Medicine and Pathology* 5:95-99.
- George RM. 1987. The lateral craniographic method of facial reconstruction. *Journal of Forensic Sciences* 32(5):1305-1330.
- George RM. 1993. Anatomical and artistic guidelines for forensic facial reconstruction. In: Iscan MY, Helmer RP, editors. *Forensic analysis of the skull: craniofacial analysis, reconstruction, and identification*. New York: Wiley-Liss. p 215-227.
- George RM. 2007. *Facial geometry: graphic facial analysis for forensic artists*. Springfield Illinois: Charles C Thomas.
- Gerasimov MM. 1955. *The reconstruction of the face from the basic structure of the skull*. Moscow: Nauka.
- Gerasimov MM. 1971. *The face finder*. Philadelphia: J.B. Lippincott.
- Gombrich EH. 1982. *The mask and the face: the perception of physiognomic likeness in life and art. The image and the eye: further studies in the psychology of pictorial representation*. Oxford: Phaidon.
- González-José R, Ramirez-Rozzi F, Sardi M, Martínez-Abadías N, Hernández M, Pucciarelli H. 2005. Functional-cranial approach to the influence of economic strategy on skull morphology. *American Journal of Physical Anthropology* 128:757-771.
- Gonzalez PN. 2008. *Morfometría geométrica aplicada al análisis del dimorfismo sexual en restos óseos humanos de individuos adultos y subadultos*. Unpublished PhD Thesis. Universidad Nacional de La Plata, La Plata.
- Gonzalez P, Perez SI, Bernal V. 2010. Ontogeny of robusticity of craniofacial traits in modern humans: A study of South American populations. *American Journal of Physical Anthropology* 142:367-379.
- Graw M. 2001. Significance of the classical morphological criteria for identifying gender using recent skulls. *Forensic Science Communications* 3(1).
- Hayes S, Buckley H, Bradley R, Milne N, Dennison J. 2011. Approximating the face of 'Aunty': A question of likeness. *Journal of Archaeological Method and Theory*. DOI 10.1007/s10816-011-9115-2.
- Hayes S, Valentin F, Buckley H, Spriggs M, Bedford S. 2009. Faces of the Teouma Lapita people: Art, accuracy and facial approximation. *Leonardo* 42(3):284-285.
- Helmer RP, Rochricht S, Petersen D, Mohr F. 1993. Assessment of the reliability of facial reconstruction. In: Iscan MY, Helmer RP, editors. *Forensic analysis of the skull: craniofacial analysis, reconstruction, and identification*. New York: Wiley-Liss. p 229-246.
- Kustar A. 1999. Facial reconstruction of an artificially distorted skull of the 4th to the 5th century from the site of Mozs. *International Journal of Osteoarchaeology* 9:325-332.
- Kustar A. 2004. The facial restoration of Antal Simon, a Hungarian priest-teacher of the 19th c. *HOMO* 55:77-90.
- Larrabee W, Makielski K. 1993. *Surgical anatomy of the*

## A MAN FROM SAN JUAN

- face. New York: Raven.
- Macho GA. 1989. Descriptive morphological features of the nose - an assessment of their importance for plastic reconstruction. *Journal of Forensic Sciences* 34(4):902-911.
- Needham C. 2002. Drawing the past: reconstructing the visual manifestations of disease and trauma from archaeological human remains [M Phil]. Manchester: University of Manchester.
- Perez SI. 2006. Artificial cranial deformation in South America: a geometric morphometrics application. *Journal of Archaeological Science* 34:1649-1658.
- Phenice TW. 1969. A newly developed visual method of sexing the os pubis. *American Journal of Physical Anthropology* 30(2):297-301.
- Prag J, Neave R. 1997. Making faces: using forensic and archaeological evidence. London: British Museum Press.
- Rynn C, Wilkinson M, Peters H. 2010. Prediction of nasal morphology from the skull. *Forensic Science, Medicine and Pathology* 6(1):20.
- Sardi M, Béguelin M. 2010. Skeletal differentiation at the southernmost frontier of Andean agriculture. In: Pinhasi R, Stock J, editors. *Human bioarchaeology of the transition to agriculture*. Oxford: John Wiley & Sons. p 429-450.
- Sardi M, Novellino P, Pucciarelli H. 2006. Craniofacial morphology in the Argentine Centre-West: Consequences of the transition to food production. *American Journal of Physical Anthropology* 130:333-343.
- Shepherd J, Davies G, Ellis H. 1981. Studies of cue saliency. In: Davies G, Ellis H, Shepherd J, editors. *Perceiving and remembering faces*. London: Academic Press. p 105-131.
- Snow CC, Gatliff BP, McWilliams KR. 1970. Reconstruction of facial features from the skull: an evaluation of its usefulness in forensic anthropology. *American Journal of Physical Anthropology* 33:221-228.
- Standring S. 2008. *Gray's Anatomy: The anatomical basis of clinical practice*. Elsevier.
- Stephan CN. 2002. Facial approximation: globe projection guideline falsified by exophthalmometry literature. *Journal of Forensic Sciences* 47(4):730-735.
- Stephan CN. 2003. Facial approximation: An evaluation of mouth-width determination. *American Journal of Physical Anthropology* 121(1):48-57.
- Stephan CN, Henneberg M, Sampson W. 2003. Predicting nose projection and pronasale position in facial approximation: a test of published methods and proposal of new guidelines. *American Journal of Physical Anthropology* 122:240-250.
- Stephan CN, Simpson EK. 2008. Facial soft tissue depths in craniofacial identification (Part 1): An analytical review of the published adult data. *Journal of Forensic Sciences* 53(6):1257-1272.
- Steward JH. 1946. *Handbook of South American Indians*. Washington: Smithsonian Institution Bureau of American Ethnology Bulletin.
- Taylor KT. 2001. *Forensic art and illustration*. Boca Raton: CRC Press.
- Taylor RG, Angel C. 1998. Facial reconstruction and approximation. In: Clement JG, Ranson DL, editors. *Craniofacial identification in forensic medicine*. London: Arnold. p 177-186.
- Tiesler V, Cucina A, Pacheco R. 2004. Who was the Red Queen? Identity of the female Maya dignitary from the sarcophagus tomb of Temple XIII, Palenque, Mexico. *HOMO* 55:65-76.
- Warwick R, Williams P. 1973. *Gray's Anatomy*. Edinburgh: Longman.
- Wilkinson C. 2004. *Forensic facial reconstruction*. Cambridge: Cambridge University Press.
- Wilkinson C, Motwani M, Chiang E. 2003. The relationship between the soft tissues and the skeletal detail of the mouth. *Journal of Forensic Science* 48(4):728-232.
- Wilkinson C, Neave R. 2003. The reconstruction of a face showing a healed wound. *Journal of Archaeological Science* 30:1343-1348.
- Woo TL. 1931. On the asymmetry of the human skull. *Biometrika* 22(3/4):324.